

Musterschreiben Impfung im Gesundheitswesen

Sehr geehrte/r Herr/Frau _____ (Name des Arbeitgebers oder der zuständigen Ansprechperson beim Arbeitgeber)

Sie haben mit Schreiben vom ____/auf einer Personalversammlung am ____/in einem am ____ geführten Gespräch angekündigt, dass Sie mich ab dem 16.3.2022 weder weiter beschäftigen noch weiterbezahlen werden, wenn ich bis dahin keinen Nachweis einer Impfung gegen SARS CoV-2 vorgelegt habe.

I. Wirksame Einwilligung unter Druck unmöglich

Nach wie vor bin ich demgegenüber fest entschlossen, mich einer solchen Impfung nicht zu unterziehen. Und ich kann Sie nur davor warnen, den Druck „Impfung oder Kündigung/unbezahlte Freistellung“ aufrechtzuerhalten. Denn Sie begeben sich juristisch auf heikles Terrain.

Ich mache Sie nämlich hiermit darauf aufmerksam, dass ich unter dem Druck, unter den Sie mich setzen, überhaupt keine wirksame Impfeinwilligung erteilen kann. Kein Arzt der Welt kann mich jetzt noch impfen, ohne dass er sich seinerseits strafbar und schadensersatzpflichtig macht.

Für die Impfung gegen SARS CoV-2 gelten die gleichen Grundsätze wie für jeden anderen medizinischen Eingriff: Es handelt sich um eine tatbestandsmäßige Körperverletzung, die nur rechtmäßig ist, wenn und weil sie von der Einwilligung des Patienten gedeckt ist. Eine wirksame Einwilligung ist nur dann gegeben, wenn (1.) dem Eingriff eine ordnungsgemäße Aufklärung über Nutzen und Risiken vorausgegangen ist und (2.) die Einwilligung nicht unter Druck erteilt worden ist. Die Drohung, die Grundlage der Finanzierung meines Lebensunterhalts zu verlieren, entfaltet eine so starke erhebliche Druckwirkung, dass eine wirksame Impfeinwilligung unter diesen Umständen ausgeschlossen ist.

II. Haftungsrechtliche Konsequenzen

Da Sie mich vor die Alternative stellen, mich entweder impfen zu lassen oder ab dem 16.3.2022 ohne Bezahlung dazustehen, wären Sie, wenn ich mich denn unter diesem Druck impfen ließe, unter dem Gesichtspunkt der mittelbaren Täterschaft (§ 25 Abs. 1, 2. Alt. StGB) persönlich dafür verantwortlich, dass an mir in Gestalt der COVID-19-Impfung eine solche Körperverletzung begangen wird. Nun legen Sie es mit dem Druck, den Sie auf mich ausüben, auf genau eine solche Impfung und damit auf eben diese Körperverletzung an. Damit verwirklicht die von Ihnen ausgesprochene Drohung den Tatbestand eines strafbaren Versuchs der gefährlichen Körperverletzung (§§ 224 Abs. 1 Nr. 1 und 5, Abs. 2, 22 StGB). Außerdem verwirklicht Ihre Drohung, dass ich meinen Arbeitsplatz verliere, wenn ich mich nicht impfen lasse, den Tatbestand der versuchten Nötigung (§§ 240 Abs. 1, Abs. 2, 22 StGB). Bei allen genannten Vorschriften handelt es sich um Schutzgesetze im Sinne von § 823 Abs. 2 BGB. **Sie haften damit persönlich für alle Schäden, die mir dadurch entstehen, dass Sie versuchen, mich mit existenzbedrohendem Druck zur Impfung zu drängen.**

Und sogar noch schwerere Straftatbestände können – jeweils in der Form des strafbaren Versuchs – erfüllt sein. Die Impfungen sind nämlich entgegen verbreiteter Berichterstattung in den Altmedien keinesfalls sicher. Die Schäden durch die COVID-Impfungen können vielmehr beträchtliche Ausmaße annehmen; es wäre, wenn ich mich denn impfen ließe, sogar möglich, dass ich an der Impfung sterbe. Näheres entnehmen Sie bitte dem aktuellen Sicherheitsbericht des Paul-Ehrlich-Instituts:

https://www.pei.de/SharedDocs/Downloads/DE/newsroom/dossiers/sicherheitsberichte/sicherheitsbericht-27-12-20-bis-30-11-21.pdf?__blob=publicationFile&v=7.

Mittlerweile sind die hoch gefährlichen und teilweise tödlichen **Impfnebenwirkungen** in mehr als **1.000 wissenschaftlichen Studien** beschrieben (siehe die Auflistung in Anlage 1) – und täglich kommen neue Studien dazu. Es erscheint immer schwerer begreiflich, wie viel wissenschaftliche Evidenz die Menschheit noch benötigt, um zu erkennen, dass die in Deutschland zugelassenen COVID-Impfstoffe massive gesundheitliche Schäden anrichten.

Es häufen sich zudem seit dem Impfstart **Medienberichte**, wonach Menschen nach der Impfung „plötzlich und unerwartet“ von uns gehen oder jedenfalls schwerste Schäden davontragen:

<https://journalistenwatch.com/2022/01/10/gepiekst-und-verstorben-ploetzlich-und-unerwartet/>.

<https://covvaxse.com/confirmed-media-reports-of-covid-19-vaccine-deaths/>.

Besonders erschütternd ist der am 24.1.2022 veröffentlichte Selbstbericht eines Mitarbeiters der Mainzer Stadtverwaltung, der nach der Impfung unter wochenlangen massiven Schmerzen litt und schließlich mit knapper Not einen ischämischen Schlaganfall überlebte:

<https://www.berliner-zeitung.de/news/seit-meiner-impfung-ist-nichts-mehr-wie-es-war-li.207931>.

Sehenswert ist auch die zweiteilige Dokumentation des Schicksals Impfgeschädigter auf SERVUS.TV:

Teil 1 (19.1.2022): Im Stich gelassen – die COVID-Impfopfer:
<https://www.servustv.com/aktuelles/v/aa1uhra88dp5llzqs7cp/>.

Teil 2 (27.1.2022): COVID-Impfopfer – Geschädigte, die es nicht geben darf:
<https://www.servustv.com/aktuelles/v/aa2fcz9y1l5c4uuygsjz/>.

Sämtliche dieser Berichte zeigen, dass die Betroffenen (wohlgemerkt: das sind jene, die es überlebt haben!) nicht nur schwerstem Leid ausgesetzt sind, sondern von den relevanten Akteuren auch noch verhöhnt werden: von Ärzten, die vor dem Zusammenhang mit der Impfung geflissentlich die Augen verschließen, und vor Behörden, die sich ungeachtet der schweren Nebenwirkungen allen Ernstes weigern, für weitere Impfungen eine Kontraindikation anzuerkennen.

Selbst den Herstellern der COVID-Impfstoffe bleiben die fatalen Nebenwirkungen nicht verborgen. Auf gerichtliche Anordnung musste die US-amerikanische Food And Drugs Administration (FDA) interne und als vertraulich eingestufte Dokumente herausgeben, die sich auf den Pfizer/BioNTech-Impfstoff „Comirnaty“ beziehen – jenen Impfstoff also, der in Deutschland mit Abstand am häufigsten verabreicht wird. Aus einem dieser Dokumente geht hervor, dass Pfizer bereits bis Ende Februar 2021, also keine drei Monate nach dem Impfstart, von 1.223 (!) Fällen Kenntnis erlangt hatte, in denen die Impfung einen tödlichen Ausgang genommen hatte:

<https://phmpt.org/wp-content/uploads/2021/11/5.3.6-postmarketing-experience.pdf> (siehe dort Tabelle Seite 7).

Wollen Sie den Fortbestand meines Arbeitsverhältnisses allen Ernstes davon abhängig machen, dass ich in Gestalt der COVID-Impfung mein Leben oder aber zumindest schwerste bleibende Gesundheitsschäden riskiere?

Verlautbarungen von Politikern, regierungstreuen Medien, Ärztekammern und Berufsverbänden, die COVID-Impfungen seien sicher, entbehren jeglicher Grundlage. Aussagen etwa des Inhalts, es gebe keinen Grund, sich nicht impfen zu lassen, sind durch die Studienlage klar widerlegt. Soweit „Impfverweigerer“ gar zum Feindbild stilisiert und z. B. als Sozialschädlinge, als asoziale Trittbrettfahrer oder als Schuldige an der Fortdauer der Corona-Maßnahmen beschimpft werden,

handelt es sich um faktenferne Propaganda, die nur darauf abzielt, durch Ausgrenzung weiteren psychischen Druck zu erzeugen.

III. Neueste Erkenntnisse: Unterschiedlich dosierte Chargen

Eine wirksame Impfeinwilligung kann ich darüber hinaus deshalb nicht abgeben, weil jeder, der sich gegen SARS CoV-2 impfen lässt, an einer experimentellen klinischen Studie teilnimmt, ohne nach seiner Einwilligung gefragt worden zu sein. Es gibt nämlich mittlerweile erdrückende Beweise dafür, dass die Impfstoffhersteller Pfizer/BioNTech, Moderna und Johnson & Johnson zielgerichtet Chargen mit unterschiedlichen Inhalten in den Verkehr bringen. Ablesen kann man dies insbesondere anhand der Daten aus dem Vaccine Adverse Events Reporting System (VAERS) in den USA. Die Nebenwirkungsrisiken sind in einigen Chargen dramatisch erhöht. Was mit diesen unterschiedlichen Inhalten bezweckt wird, gilt es derzeit zu ermitteln. Nicht auszuschließen ist, dass die Hersteller derzeit ausprobieren, bei welcher Dosierung sich welche (Neben-)Wirkungen einstellen; ebenso denkbar ist, dass die Hersteller unterschiedliche Hilfsstoffe (Adjuvantien) einsetzen und deren Wirkung beobachten wollen. Näheres entnehmen Sie bitte dem als Anlage 2 beigefügten Medienbericht.

Insbesondere die Hypothese eines Dosis-Experiments wäre, wenn sie sich bewahrheiten sollte, fatal. Untersuchungen zur Adjustierung der Dosis hätten nämlich eigentlich längst in einer klinischen Phase-II-Studie angestellt werden müssen, also bevor die COVID-Impfstoffe überhaupt auch nur eine bedingte Zulassung erhielten. Aber selbst wenn es sich nicht um ein Dosis-Experiment handeln sollte: Allein schon die Tatsache, dass nicht in allen Impfstoff-Flaschen dasselbe enthalten ist, ist hochgradig kriminell. Es ist schon schlimm genug, dass ich von Ihnen zur Einwilligung in eine experimentelle Impfung gezwungen werden soll. **Es ist aber noch etwas völlig anderes, ob ich in eine Impfung oder aber in die Teilnahme an einer klinischen Studie einwillige.** Letzteres kommt für mich **unter gar keinen Umständen in Betracht.** Ich weigere mich strikt, meinen Körper der Pharmaindustrie als Versuchsobjekt zur Verfügung zu stellen!

IV. Keine Rechtfertigung der Impferpressung durch § 20a IfSG

Ihre Drohung, mein Arbeitsverhältnis ohne COVID-Impfung zu beenden oder mich unbezahlt freizustellen, lässt sich auch nicht mit dem Hinweis rechtfertigen, Sie hätten lediglich dem Normbefehl des § 20a IfSG Folge geleistet. Richtig ist vielmehr, dass Sie mich weiterbeschäftigen dürfen, bis das Gesundheitsamt ein Betretungsverbot ausspricht. Dies haben Juristen des Netzwerks Kritische Richter und Staatsanwälte in zwei Beiträgen näher herausgearbeitet:

<https://netzwerkkrista.de/2021/12/28/weiterarbeit-im-gesundheitssektor-trotz-fehlender-impfung-moeglich-kann-regelung-in-%c2%a7-20a-abs-5-infektionsschutzgesetz-laesst-gesundheitsaemtern-spielraum-pflegekat/>.

<https://netzwerkkrista.de/2022/01/05/ist-die-weiterbeschaeftigung-eines-arbeitnehmers-ohne-immunitaetsnachweis-im-gesundheitswesen-ab-dem-16-maerz-2022-fuer-den-arbeitgeber-eine-ordnungswidrigkeit-solange-seitens-des-gesundheitsamtes-k/>.

Und am 25.1.2022 antwortete die Bundesregierung auf eine parlamentarische Anfrage, ob angesichts des § 20a IfSG mit einer Kündigungswelle im Gesundheitswesen zu rechnen sei, folgendes (Bundestags-Drucksache 20/477, Seite 6 am Ende):

„Die in § 20a des Infektionsschutzgesetzes geregelte einrichtungsbezogene Impfpflicht für Bestandspersonal zieht kein automatisches Beschäftigungsverbot nach sich. Bei Nichtvorlage eines geeigneten Nachweises (Impf- oder Genesenennachweis oder Zeugnis über medizinische

Kontraindikation) ist diese zunächst dem Gesundheitsamt zu melden. Bei Nichtvorlage des Nachweises trotz Aufforderung entscheidet das zuständige Gesundheitsamt nach pflichtgemäßem Ermessen im Einzelfall über die weiteren Maßnahmen (z. B. ein Betretungs- oder Tätigkeitsverbot) und wird dabei auch die Personalsituation in der Einrichtung berücksichtigen.“

Ob also das Gesundheitsamt ein solches Betretungsverbot ausspricht, ist nach alledem keinesfalls gesichert; der Erlass eines solchen Verbots liegt vielmehr im Ermessen des Gesundheitsamts. Für die Ausübung dieses Ermessens wird es eine ganz wesentliche Rolle spielen, wie sich der Wegfall von Beschäftigten, die nicht gegen SARS CoV-2 geimpft sind, auf die Beanspruchung der Ressourcen im Gesundheitswesen auswirkt. Es ist mit anderen Worten **Ihre Aufgabe als Arbeitgeber, den Gesundheitsämtern klarzumachen, dass sie einen absoluten Notstand bei der Patientenversorgung riskieren, wenn sie von ihren in § 20a IfSG niedergelegten Befugnissen Gebrauch machen.** Sie können z. B. darauf verweisen, dass auch die Impfungen Corona-Ausbrüche in Kliniken nicht haben verhindern können. So wurde über einen Ausbruch im Düsseldorfer Universitätsklinikum berichtet:

https://rp-online.de/nrw/staedte/duesseldorf/duesseldorf-corona-ausbruch-an-der-uniklinik_aid-64044707.

Ebenso im Dietrich-Bonhoeffer-Klinikum in Neubrandenburg:

<https://dbknb.de/aktuelles/show-startseite-extern/post/besuchsstopp-in-der-psychiatrie-nach-corona-ausbruch>.

Ebenso in einer Reha-Klinik in Wuppertal:

<https://www.rnd.de/panorama/wuppertal-corona-ausbruch-in-reha-klinik-aufnahmestopp-angeordnet-4D4HVMVNHZWK2VPDROR673AQLXM.html>.

Ebenso im Bergmann-Klinikum in Potsdam:

<https://www.berlin.de/aktuelles/brandenburg/7127086-5173360-erneut-coronaausbruch-im-bergmannkliniku.html>.

Zuletzt im Sana-Klinikum im brandenburgischen Woltersdorf:

<https://www.moz.de/lokales/erkner/covid-faelle-an-klinik-corona-ausbruch-im-sana-krankenhaus-woltersdorf-so-ist-der-aktuelle-stand-61957257.html>.

In Großbritannien ist der Notstand so alarmierend, dass in den Kliniken schon das Militär eingesetzt werden muss, um einen halbwegs funktionierenden Betrieb aufrechtzuerhalten:

https://www.aerztezeitung.de/Politik/Britische-Krankenhaeuser-setzen-wegen-Corona-jetzt-das-Militaer-ein-425863.html?utm_source=dlvr.it&utm_medium=facebook&fbclid=IwAR1f2XnSw5i2oo4m0Gh6cH8ZZvFNXoDzPIAe5XXr13zXqnVIGQmwBzFemHl.

All dies haben die COVID-Impfungen nicht verhindern können. Ganz im Gegenteil: Mit großer Wahrscheinlichkeit haben sie die dramatische Situation sogar noch befeuert! Eine Analyse der Statistiken aus 145 Ländern (Beattle, K.: Worldwide Bayesian Causal Impact Analysis of Vaccine Administration on Deaths and Cases Associated with COVID-19: A BigData Analysis of 145 Countries, Preprint vom 15.11.2021) mündete in das folgende Ergebnis:

The results of this study taken together demonstrate a product that directly causes more COVID-19 associated cases and deaths than otherwise would have existed with zero vaccines.

Wer sich daran stört, dass diese Studie noch keine Peer Review durchlaufen hat, möge sich im *European Journal of Epidemiology* vom 30.9.2021 kundig machen: Eine umfassende Datenanalyse in 68 Ländern und 2.947 US-Landkreisen ergab keine Korrelation zwischen der Impfquote und dem Anstieg der COVID-19-Fälle (Subramanian, S.V./Kumar, A., Increases in COVID-19 are unrelated to levels of vaccination across 68 countries and 2947 counties in the United States, <https://doi.org/10.1007/s10654-021-00808-7>). Damit ist auf breiter Fläche die Nutzlosigkeit der COVID-Impfungen bewiesen.

Aber mehr noch: Unter der Überschrift „Findings“ findet sich die Aussage, dass der Trend sogar eher in die Richtung „höhere Impfquote – mehr Fälle“ ausschlägt. Und in der Tat: Als weiterer Beleg sei auf die folgende in *The Lancet* veröffentlichte Arbeit verwiesen, in der für eine größere Kohorte von über 60jährigen Menschen festgestellt wurde, dass 89,7% der COVID-Patienten vollständig geimpft waren (Kampf, G, The epidemiological relevance of the COVID-19-vaccinated population is increasing, *The Lancet Regional Health – Europe* 11 (2021) 100272, <https://doi.org/10.1016/j.lanepe.2021.100272>). Die Impfungen nützen also nicht nur nichts – sie machen vielmehr alles noch viel schlimmer!

Sollten, bedingt durch Impfschäden, weitere Mitarbeiterinnen und Mitarbeiter im Gesundheitswesen ausfallen, werden sich auch in Deutschland die Probleme drastisch verschärfen.

Es sollte Ihnen nicht schwerfallen, das Gesundheitsamt davon zu überzeugen, dass Sie weiterhin auf die Arbeitskraft Ihrer ungeimpften Mitarbeiterinnen und Mitarbeiter angewiesen sind. In den USA sind Versuche, die Belegschaften in den Kliniken zwangsweise komplett durchzuimpfen, kläglich gescheitert, weil viele Beschäftigte diesem Zwang trotzten. Die Kliniken mussten klein begeben und von verpflichtenden Impfungen wieder Abstand nehmen:

<https://www.welt.de/wirtschaft/plus235726948/USA-Impfpflicht-aufgehoben-Amerikas-Kliniken-droht-der-Aerzte-Exodus.html>?

Das gleiche wird auch in Deutschland passieren. **Auch hierzulande wird das Personal in Scharen dem Gesundheitswesen den Rücken kehren, wenn vom Impfwang nicht abgelassen wird.** Auch in Ihrem Hause droht dann ein Personalnotstand! Setzen Sie daher bitte nicht Ihre Belegschaft unter Druck, sondern die Gesundheitsämter – im Interesse einer zuverlässigen Patientenversorgung!

V. Kein Mehrwert durch die COVID-Impfungen

Ein Mehrwert der Impfungen für die Prävention gegen COVID-19-Erkrankungen ist zum gegenwärtigen Zeitpunkt nicht ersichtlich. Denn auch in Deutschland herrscht mittlerweile die Omikron-Variante vor. Ihre Entdeckerin, eine Ärztin aus Südafrika, hat sich entsetzt über die Art und Weise geäußert, wie diese Variante in Europa zum Zweck der Panikmache eingesetzt wird; in Wirklichkeit handelt es sich um eine Variante, die so harmlos erscheint, dass die Chance besteht, auf natürlichem Wege Herdenimmunität zu erreichen, wenn man die Durchseuchung der Bevölkerung mit diesem Erreger einfach zulässt:

https://www.focus.de/gesundheit/coronavirus/aerztin-aus-suedafrika-aerztin-die-variante-entdeckte-wenn-wir-ueberreagieren-laufen-wir-gefahr-die-vorteile-von-omikron-zu-verpassen_id_24536158.html.

Die spanische Regierung hat daraus bereits die Konsequenz gezogen, COVID-19 mit Blick auf Omikron auf den Status einer normalen Grippe herabzustufen:

<https://deutsche-wirtschafts-nachrichten.de/516819/Spanien-behandelt-Corona-fortan-wie-eine-gewoehnliche->

[Grippe?utm_content=link_4&utm_medium=email&utm_campaign=dwn_telegramm&utm_source=mid1000&f_tid=dae4aea3cbc7d675e751a8ff0bf80f46.](https://www.aerztezeitung.de/Nachrichten/WHO-Die-Haelfte-Europas-koennte-in-acht-Wochen-mit-Omikron-infiziert-sein-425916.html?utm_source=dlvr.it&utm_medium=facebook&fbclid=IwAR3wZUOXY39BJMfp2pu8MmhZjbDYFWTiov-rHgcljGw9Z_Ts5cf0iOtSZHQ)

Diese Vorgehensweise wird gestützt durch die Einschätzung der EMA, dass SARS CoV-2 in der Omikron-Variante endemisch werden könnte, d.h. (spätestens) jetzt der Zeitpunkt erreicht sei, da das menschliche Immunsystem auf breiter Fläche auf den Erreger vorbereitet sei.

[https://www.aerztezeitung.de/Nachrichten/WHO-Die-Haelfte-Europas-koennte-in-acht-Wochen-mit-Omikron-infiziert-sein-425916.html?utm_source=dlvr.it&utm_medium=facebook&fbclid=IwAR3wZUOXY39BJMfp2pu8MmhZjbDYFWTiov-rHgcljGw9Z_Ts5cf0iOtSZHQ.](https://www.aerztezeitung.de/Nachrichten/WHO-Die-Haelfte-Europas-koennte-in-acht-Wochen-mit-Omikron-infiziert-sein-425916.html?utm_source=dlvr.it&utm_medium=facebook&fbclid=IwAR3wZUOXY39BJMfp2pu8MmhZjbDYFWTiov-rHgcljGw9Z_Ts5cf0iOtSZHQ)

Je näher wir auf den Zustand zusteuern, dass SARS CoV-2 zum ganz normalen Bestandteil des alljährlichen Infektionsgeschehens wird, desto weniger besteht die Notwendigkeit, einen experimentellen, bis heute nur mit einer bedingten Zulassung ausgestatteten Impfstoff einzusetzen – schon gar nicht mit dem Mittel des Zwangs.

Will man Prävention gegen einen akuten Atemwegsinfekt betreiben (und zwar gleichviel mit welchem Erreger!), besteht eine **kostengünstigere und effektivere Möglichkeit allein schon in Gestalt eines ausreichend hohen Vitamin-D-Spiegels**. Zahlreiche Studien haben den Nachweis erbracht, dass schwere und tödliche Verläufe von COVID-19 auf diese Weise verhindert werden können. Hier eine Auswahl (weitere Studien werden auf Wunsch gerne nachgereicht):

- Borsche, L.; Glauner, B.; von Mendel, J.: COVID-19 Mortality Risk Correlates Inversely with Vitamin D3 Status, and a Mortality Rate Close to Zero Could Theoretically Be Achieved at 50 ng/mL 25(OH)D3: Results of a Systematic Review and Meta-Analysis. *Nutrients* **2021**, *13*, 3596. <https://doi.org/10.3390/nu13103596>.
- Yisak, H. et al.: Effects of Vitamin D on COVID-19 Infection and Prognosis: A Systematic Review, Risk Management and Healthcare Policy 2021:14 31–38, <http://doi.org/10.2147/RMHP.S291584>.
- Petrelli, F. et al., Therapeutic and prognostic role of vitamin D for COVID-19 infection: A systematic review and meta-analysis of 43 observational studies, *Journal of Steroid Biochemistry and Molecular Biology* 211 (2021) 105883, <https://doi.org/10.1016/j.jsbmb.2021.105883>.

Wohlgedenkt: Allein schon Vitamin D hat einen hohen prophylaktischen Effekt. Weitere mögliche Optionen der Prophylaxe und der Therapie sind hier noch nicht erwähnt; gerne reiche ich hierzu auf Wunsch ebenfalls zusätzliche Informationen nach.

Wenn Sie Ihre Fürsorgepflicht gegenüber Ihrer Belegschaft wirklich ernst nehmen, werden Sie dies alles gegenüber den Gesundheitsämtern vortragen. Wenn dem Gesundheitsamt an der Vermeidung eines Gesundheitsnotstandes gelegen ist, wird es von Betretungsverboten absehen, und ich kann ganz normal weiterhin meiner Arbeit nachgehen.

VI. Abschließende Erklärung zum weiteren Vorgehen

Ich fordere Sie hiermit auf, mir gegenüber rechtsverbindlich zu erklären, dass Sie, solange das Gesundheitsamt kein Betretungsverbot ausspricht, den Bestand meines Arbeitsverhältnisses selbst dann nicht in Frage stellen und mein Arbeitsentgelt selbst dann weiterhin bezahlen werden, wenn ich mich nicht impfen lasse. Ferner erwarte ich von Ihnen, dass Sie alles daran setzen, dass das Gesundheitsamt ein Betretungsverbot gar nicht erst ausspricht. Ich selbst beabsichtige, mich im Falle eines Betretungsverbots gerichtlich dagegen zu wehren.

Sollten Sie diese Erklärung nicht abgeben, werde ich rechtliche Schritte in Erwägung ziehen, insbesondere die folgenden:

- Im Falle einer Kündigung: Kündigungsschutzklage. Ein Recht zur fristlosen Kündigung steht Ihnen nicht zu. Meine Weigerung, mich impfen zu lassen, lässt sich nicht als Verletzung meiner Pflichten aus dem Arbeitsverhältnis qualifizieren – und zwar allein schon deshalb nicht, weil ich in die Impfung gar nicht mehr wirksam einwilligen *kann*. Aus dem gleichen Grund scheidet eine verhaltensbedingte Kündigung aus. Und für eine personenbedingte Kündigung ist kein Raum, solange das Gesundheitsamt kein Betretungsverbot ausspricht.
- Im Falle einer unbezahlten Freistellung: Lohnfortzahlungsklage auf der Basis des § 615 BGB sowie Klage auf vertragsgemäße Weiterbeschäftigung. Ich werde meine Arbeitskraft auch in der Zeit nach dem 15.3.2022 ordnungsgemäß anbieten. Und solange das Gesundheitsamt kein Betretungsverbot ausspricht, werden Sie meine Arbeitsleistung annehmen müssen. Solange Sie mir die Zahlung meines Arbeitsentgelts verweigern, werde ich gemäß § 157 Abs. 3 SGB III Arbeitslosengeld I beantragen. Sie müssen dann damit rechnen, von der Agentur für Arbeit in Regress genommen zu werden.
- Einstweilige Verfügung auf Unterlassung weiterer Versuche, mich zur Impfung zu zwingen. Die Anspruchsgrundlage § 823 Abs. 2 BGB i. V. m. §§ 223 ff., 240 StGB trägt nicht nur einen Schadensersatz-, sondern ebenso einen Unterlassungsanspruch. Der Impfdruck verkörpert außerdem zu meinem Nachteil eine vorsätzliche sittenwidrige Schädigung, die gemäß § 826 BGB zu unterlassen ist. Soweit es um die Verletzung meines Körpers geht, stehen mir ferner Unterlassungsansprüche nach § 823 Abs. 1, § 1004 Abs. 1 BGB analog zu. Eine solche Verfügung kann sich gegen jeden richten, der den Impfdruck erzeugt oder aufrechterhält, und damit insbesondere auch gegen Sie persönlich! (Jetzt folgt noch ein Satz für Fälle, in denen Träger der Einrichtung eine OHG, eine KG, GmbH, eine Aktiengesellschaft, eine Genossenschaft oder ein vergleichbarer rechtsfähiger Personenverband ist – bitte füllen Sie also das *Nachstehende* nur aus und schreiben Sie es nur dann, wenn dies auf Ihren Arbeitgeber zutrifft!) Sie können sich insbesondere nicht dahinter verstecken, dass Sie für eine selbständig rechtsfähige (OHG, KG, GmbH, Aktiengesellschaft, Genossenschaft etc. – bitte das Zutreffende einsetzen) tätig geworden sind. Für den Schaden, den Sie mir durch eine unerlaubte Handlung zufügen, haben Sie vielmehr persönlich geradzustehen. Und deshalb sind Sie auch persönlich unterlassungspflichtig.

Mit freundlichen Grüßen

(Name)

Anlage 1 Impfung im Gesundheitswesen

Studienliste Impfnebenwirkungen

Over 1100 scientific studies and/or reports on the dangers associated with COVID injections related to blood clotting, myocarditis, pericarditis, thrombosis, thrombocytopenia, anaphylaxis, Bell's palsy, Guillain-Barre, deaths, etc.

1. Cerebral venous thrombosis after COVID-19 vaccination in the UK: a multicenter cohort study: [https://www.thelancet.com/journals/lancet/article/PIIS0140-6736\(21\)01608-1/fulltext](https://www.thelancet.com/journals/lancet/article/PIIS0140-6736(21)01608-1/fulltext)
2. Vaccine-induced immune thrombotic thrombocytopenia with disseminated intravascular coagulation and death after ChAdOx1 nCoV-19 vaccination: <https://www.sciencedirect.com/science/article/pii/S1052305721003414>
3. Fatal cerebral hemorrhage after COVID-19 vaccine: <https://pubmed.ncbi.nlm.nih.gov/33928772/>
4. Myocarditis after mRNA vaccination against SARS-CoV-2, a case series: <https://www.sciencedirect.com/science/article/pii/S2666602221000409>
5. Three cases of acute venous thromboembolism in women after vaccination against COVID-19: <https://www.sciencedirect.com/science/article/pii/S2213333X21003929>
6. Acute thrombosis of the coronary tree after vaccination against COVID-19: <https://www.sciencedirect.com/science/article/abs/pii/S1936879821003988>
7. US case reports of cerebral venous sinus thrombosis with thrombocytopenia after vaccination with Ad26.COV2.S (against covid-19), March 2 to April 21, 2020: <https://pubmed.ncbi.nlm.nih.gov/33929487/>
8. Portal vein thrombosis associated with ChAdOx1 nCov-19 vaccine: [https://www.thelancet.com/journals/langas/article/PIIS2468-1253\(21\)00197-7/fulltext](https://www.thelancet.com/journals/langas/article/PIIS2468-1253(21)00197-7/fulltext)
9. Management of cerebral and splanchnic vein thrombosis associated with thrombocytopenia in subjects previously vaccinated with Vaxzevria (AstraZeneca): position statement of the Italian Society for the Study of Hemostasis and Thrombosis (SISET): <https://pubmed.ncbi.nlm.nih.gov/33871350/>
10. Vaccine-induced immune thrombotic thrombocytopenia and cerebral venous sinus thrombosis after vaccination with COVID-19; a systematic review: <https://www.sciencedirect.com/science/article/pii/S0022510X21003014>
11. Thrombosis with thrombocytopenia syndrome associated with COVID-19 vaccines: <https://www.sciencedirect.com/science/article/abs/pii/S0735675721004381>
12. Covid-19 vaccine-induced thrombosis and thrombocytopenia: a commentary on an important and practical clinical dilemma: <https://www.sciencedirect.com/science/article/abs/pii/S0033062021000505>
13. Thrombosis with thrombocytopenia syndrome associated with COVID-19 viral vector vaccines: <https://www.sciencedirect.com/science/article/abs/pii/S0953620521001904>
14. COVID-19 vaccine-induced immune-thrombotic thrombocytopenia: an emerging cause of splanchnic vein thrombosis: <https://www.sciencedirect.com/science/article/pii/S1665268121000557>
15. The roles of platelets in COVID-19-associated coagulopathy and vaccine-induced immune thrombotic immune thrombocytopenia (covid): <https://www.sciencedirect.com/science/article/pii/S1050173821000967>
16. Roots of autoimmunity of thrombotic events after COVID-19 vaccination: <https://www.sciencedirect.com/science/article/abs/pii/S1568997221002160>
17. Cerebral venous sinus thrombosis after vaccination: the United Kingdom experience: [https://www.thelancet.com/journals/lancet/article/PIIS0140-6736\(21\)01788-8/fulltext](https://www.thelancet.com/journals/lancet/article/PIIS0140-6736(21)01788-8/fulltext)

18. Thrombotic immune thrombocytopenia induced by SARS-CoV-2 vaccine:
<https://www.nejm.org/doi/full/10.1056/nejme2106315>
19. Myocarditis after immunization with COVID-19 mRNA vaccines in members of the US military. This article reports that in “23 male patients, including 22 previously healthy military members, myocarditis was identified within 4 days after receipt of the vaccine”: <https://jamanetwork.com/journals/jamacardiology/fullarticle/2781601>
20. Thrombosis and thrombocytopenia after vaccination with ChAdOx1 nCoV-19:
https://www.nejm.org/doi/full/10.1056/NEJMoa2104882?query=recirc_curatedRelated_article
21. Association of myocarditis with the BNT162b2 messenger RNA COVID-19 vaccine in a case series of children: <https://pubmed.ncbi.nlm.nih.gov/34374740/>
22. Myocarditis and pericarditis after covid-19 vaccination:
<https://jamanetwork.com/journals/jama/fullarticle/2782900?fbclid=IwAR06pFKNFMfx7N6RbPK6bYUZ1y8xPnnCK9K5iZYIcEzhX8t68syO5JBwp3w>
23. Thrombotic thrombocytopenia after vaccination with ChAdOx1 nCov-19:
https://www.nejm.org/doi/full/10.1056/NEJMoa2104840?query=recirc_curatedRelated_article
24. Post-mortem findings in vaccine-induced thrombotic thrombocytopenia (covid-19):
<https://haematologica.org/article/view/haematol.2021.279075>
25. Pathological antibodies against platelet factor 4 after vaccination with ChAdOx1 nCoV-19. This article states: “In the absence of previous prothrombotic medical conditions, 22 patients had acute thrombocytopenia and thrombosis, mainly cerebral venous thrombosis, and 1 patient had isolated thrombocytopenia and a hemorrhagic phenotype”:
<https://www.nejm.org/doi/full/10.1056/NEJMoa2105385?query=TOC&fbclid=IwAR2ifm2TQjetAMB42YRRUIKEeqCQe-lDasIWvjMgzHHaltbuPbu6n7NIG3cic>
26. Thrombocytopenia, including immune thrombocytopenia after receiving COVID-19 mRNA vaccines reported to the Vaccine Adverse Event Reporting System (VAERS):
<https://www.sciencedirect.com/science/article/pii/S0264410X21005247>
27. Acute symptomatic myocarditis in seven adolescents after Pfizer-BioNTech COVID-19 vaccination:
<https://pediatrics.aappublications.org/content/early/2021/06/04/peds.2021-052478>
28. Aphasia seven days after the second dose of an mRNA-based SARS-CoV-2 vaccine. Brain MRI revealed an intracerebral hemorrhage (ICBH) in the left temporal lobe in a 52-year-old man.
<https://www.sciencedirect.com/science/article/pii/S2589238X21000292#f0005>
29. Comparison of vaccine-induced thrombotic episodes between ChAdOx1 nCoV-19 and Ad26.COV.2.S vaccines:
<https://www.sciencedirect.com/science/article/abs/pii/S0896841121000895>
30. Hypothesis behind the very rare cases of thrombosis with thrombocytopenia syndrome after SARS-CoV-2 vaccination:
<https://www.sciencedirect.com/science/article/abs/pii/S0049384821003315>
31. Blood clots and bleeding episodes after BNT162b2 and ChAdOx1 nCoV-19 vaccination: analysis of European data:
<https://www.sciencedirect.com/science/article/pii/S0896841121000937>
32. Cerebral venous thrombosis after BNT162b2 mRNA SARS-CoV-2 vaccine:
<https://www.sciencedirect.com/science/article/abs/pii/S1052305721003098>
33. Primary adrenal insufficiency associated with thrombotic immune thrombocytopenia induced by the Oxford-AstraZeneca ChAdOx1 nCoV-19 vaccine (VITT):
<https://www.sciencedirect.com/science/article/pii/S0953620521002363>

34. Myocarditis and pericarditis after vaccination with COVID-19 mRNA: practical considerations for care providers:
<https://www.sciencedirect.com/science/article/pii/S0828282X21006243>
35. “Portal vein thrombosis occurring after the first dose of SARS-CoV-2 mRNA vaccine in a patient with antiphospholipid syndrome”:
<https://www.sciencedirect.com/science/article/pii/S2666572721000389>
36. Early results of bivalirudin treatment for thrombotic thrombocytopenia and cerebral venous sinus thrombosis after vaccination with Ad26.COV2.S:
<https://www.sciencedirect.com/science/article/pii/S0196064421003425>
37. Myocarditis, pericarditis and cardiomyopathy after COVID-19 vaccination:
<https://www.sciencedirect.com/science/article/pii/S1443950621011562>
38. Mechanisms of immunothrombosis in vaccine-induced thrombotic thrombocytopenia (VITT) compared to natural SARS-CoV-2 infection:
<https://www.sciencedirect.com/science/article/abs/pii/S0896841121000706>
39. Prothrombotic immune thrombocytopenia after COVID-19 vaccination:
<https://www.sciencedirect.com/science/article/pii/S0006497121009411>
40. Vaccine-induced thrombotic thrombocytopenia: the dark chapter of a success story:
<https://www.sciencedirect.com/science/article/pii/S2589936821000256>
41. Cerebral venous sinus thrombosis negative for anti-PF4 antibody without thrombocytopenia after immunization with COVID-19 vaccine in a non-comorbid elderly Indian male treated with conventional heparin-warfarin based anticoagulation:
<https://www.sciencedirect.com/science/article/pii/S1871402121002046>
42. Thrombosis after COVID-19 vaccination: possible link to ACE pathways:
<https://www.sciencedirect.com/science/article/pii/S0049384821004369>
43. Cerebral venous sinus thrombosis in the U.S. population after SARS-CoV-2 vaccination with adenovirus and after COVID-19:
<https://www.sciencedirect.com/science/article/pii/S0735109721051949>
44. A rare case of a middle-aged Asian male with cerebral venous thrombosis after AstraZeneca COVID-19 vaccination:
<https://www.sciencedirect.com/science/article/pii/S0735675721005714>
45. Cerebral venous sinus thrombosis and thrombocytopenia after COVID-19 vaccination: report of two cases in the United Kingdom:
<https://www.sciencedirect.com/science/article/abs/pii/S088915912100163X>
46. Immune thrombocytopenic purpura after vaccination with COVID-19 vaccine (ChAdOx1 nCov-19):
<https://www.sciencedirect.com/science/article/abs/pii/S0006497121013963>.
47. Antiphospholipid antibodies and risk of thrombophilia after COVID-19 vaccination: the straw that breaks the camel’s back?:
<https://docs.google.com/document/d/1XzajasO8VMMnC3CdxSBKks1o7kiOLXFQ>
48. Vaccine-induced thrombotic thrombocytopenia, a rare but severe case of friendly fire in the battle against the COVID-19 pandemic: What pathogenesis?:
<https://www.sciencedirect.com/science/article/pii/S0953620521002314>
49. Diagnostic-therapeutic recommendations of the ad-hoc FACME expert working group on the management of cerebral venous thrombosis related to COVID-19 vaccination:
<https://www.sciencedirect.com/science/article/pii/S0213485321000839>
50. Thrombocytopenia and intracranial venous sinus thrombosis after exposure to the “AstraZeneca COVID-19 vaccine”:
<https://pubmed.ncbi.nlm.nih.gov/33918932/>
51. Thrombocytopenia following Pfizer and Moderna SARS-CoV-2 vaccination:
<https://pubmed.ncbi.nlm.nih.gov/33606296/>
52. Severe and refractory immune thrombocytopenia occurring after SARS-CoV-2 vaccination:
<https://pubmed.ncbi.nlm.nih.gov/33854395/>

53. Purpuric rash and thrombocytopenia after mRNA-1273 (Modern) COVID-19 vaccine: <https://www.ncbi.nlm.nih.gov/pmc/articles/PMC7996471/>
54. COVID-19 vaccination: information on the occurrence of arterial and venous thrombosis using data from Vigibase: <https://pubmed.ncbi.nlm.nih.gov/33863748/>
55. Cerebral venous thrombosis associated with the covid-19 vaccine in Germany: <https://onlinelibrary.wiley.com/doi/10.1002/ana.26172>
56. Cerebral venous thrombosis following BNT162b2 mRNA vaccination of BNT162b2 against SARS-CoV-2: a black swan event: <https://pubmed.ncbi.nlm.nih.gov/34133027/>
57. The importance of recognizing cerebral venous thrombosis following anti-COVID-19 vaccination: <https://pubmed.ncbi.nlm.nih.gov/34001390/>
58. Thrombosis with thrombocytopenia after messenger RNA vaccine -1273: <https://pubmed.ncbi.nlm.nih.gov/34181446/>
59. Blood clots and bleeding after BNT162b2 and ChAdOx1 nCoV-19 vaccination: an analysis of European data: <https://pubmed.ncbi.nlm.nih.gov/34174723/>
60. First dose of ChAdOx1 and BNT162b2 COVID-19 vaccines and thrombocytopenic, thromboembolic, and hemorrhagic events in Scotland: <https://www.nature.com/articles/s41591-021-01408-4>
61. Exacerbation of immune thrombocytopenia after COVID-19 vaccination: <https://pubmed.ncbi.nlm.nih.gov/34075578/>
62. First report of a de novo iTTP episode associated with a COVID-19 mRNA-based anti-COVID-19 vaccine: <https://pubmed.ncbi.nlm.nih.gov/34105244/>
63. PF4 immunoassays in vaccine-induced thrombotic thrombocytopenia: <https://www.nejm.org/doi/full/10.1056/NEJMc2106383>
64. Antibody epitopes in vaccine-induced immune thrombotic thrombocytopenia: <https://www.nature.com/articles/s41586-021-03744-4>
65. Frequency of positive anti-PF4 antibody/polyanion antibody tests after COVID-19 vaccination with ChAdOx1 nCoV-19 and BNT162b2: <https://ashpublications.org/blood/article-abstract/138/4/299/475972/Frequency-of-positive-anti-PF4-polyanion-antibody?redirectedFrom=fulltext>
66. Myocarditis with COVID-19 mRNA vaccines: <https://www.ahajournals.org/doi/pdf/10.1161/CIRCULATIONAHA.121.056135>
67. Myocarditis and pericarditis after COVID-19 vaccination: <https://jamanetwork.com/journals/jama/fullarticle/2782900>
68. Myocarditis temporally associated with COVID-19 vaccination: <https://www.ahajournals.org/doi/pdf/10.1161/CIRCULATIONAHA.121.055891>.
69. COVID-19 Vaccination Associated with Myocarditis in Adolescents: <https://pediatrics.aappublications.org/content/pediatrics/early/2021/08/12/peds.2021-053427.full.pdf>
70. Acute myocarditis after administration of BNT162b2 vaccine against COVID-19: <https://pubmed.ncbi.nlm.nih.gov/33994339/>
71. Temporal association between COVID-19 vaccine Ad26.COV2.S and acute myocarditis: case report and review of the literature: <https://www.sciencedirect.com/science/article/pii/S1553838921005789>
72. COVID-19 vaccine-induced myocarditis: a case report with review of the literature: <https://www.sciencedirect.com/science/article/pii/S1871402121002253>
73. Potential association between COVID-19 vaccine and myocarditis: clinical and CMR findings: <https://www.sciencedirect.com/science/article/pii/S1936878X2100485X>
74. Recurrence of acute myocarditis temporally associated with receipt of coronavirus mRNA disease vaccine 2019 (COVID-19) in a male adolescent: <https://www.sciencedirect.com/science/article/pii/S002234762100617X>

75. Fulminant myocarditis and systemic hyperinflammation temporally associated with BNT162b2 COVID-19 mRNA vaccination in two patients:
<https://www.sciencedirect.com/science/article/pii/S0167527321012286>.
76. Acute myocarditis after administration of BNT162b2 vaccine:
<https://www.sciencedirect.com/science/article/pii/S2214250921001530>
77. Lymphohistocytic myocarditis after vaccination with COVID-19 Ad26.COVS viral vector: <https://www.sciencedirect.com/science/article/pii/S2352906721001573>
78. Myocarditis following vaccination with BNT162b2 in a healthy male:
<https://www.sciencedirect.com/science/article/pii/S0735675721005362>
79. Acute myocarditis after Comirnaty (Pfizer) vaccination in a healthy male with previous SARS-CoV-2 infection:
<https://www.sciencedirect.com/science/article/pii/S1930043321005549>
80. Myopericarditis after Pfizer mRNA COVID-19 vaccination in adolescents:
<https://www.sciencedirect.com/science/article/pii/S002234762100665X>
81. Pericarditis after administration of BNT162b2 mRNA COVID-19 mRNA vaccine:
<https://www.sciencedirect.com/science/article/pii/S1885585721002218>
82. Acute myocarditis after vaccination with SARS-CoV-2 mRNA-1273 mRNA:
<https://www.sciencedirect.com/science/article/pii/S2589790X21001931>
83. Temporal relationship between the second dose of BNT162b2 mRNA Covid-19 vaccine and cardiac involvement in a patient with previous SARS-COV-2 infection:
<https://www.sciencedirect.com/science/article/pii/S2352906721000622>
84. Myopericarditis after vaccination with COVID-19 mRNA in adolescents 12 to 18 years of age: <https://www.sciencedirect.com/science/article/pii/S0022347621007368>
85. Acute myocarditis after SARS-CoV-2 vaccination in a 24-year-old man:
<https://www.sciencedirect.com/science/article/pii/S0870255121003243>
86. Important information on myopericarditis after vaccination with Pfizer COVID-19 mRNA in adolescents:
<https://www.sciencedirect.com/science/article/pii/S0022347621007496>
87. A series of patients with myocarditis after vaccination against SARS-CoV-2 with mRNA-1279 and BNT162b2:
<https://www.sciencedirect.com/science/article/pii/S1936878X21004861>
88. Takotsubo cardiomyopathy after vaccination with mRNA COVID-19:
<https://www.sciencedirect.com/science/article/pii/S1443950621011331>
89. COVID-19 mRNA vaccination and myocarditis:
<https://pubmed.ncbi.nlm.nih.gov/34268277/>
90. COVID-19 vaccine and myocarditis: <https://pubmed.ncbi.nlm.nih.gov/34399967/>
91. Epidemiology and clinical features of myocarditis/pericarditis before the introduction of COVID-19 mRNA vaccine in Korean children: a multicenter study
<https://search.bvsalud.org/global-literature-on-novel-coronavirus-2019-ncov/resource/en/covidwho-1360706>.
92. COVID-19 vaccines and myocarditis: <https://pubmed.ncbi.nlm.nih.gov/34246566/>
93. Myocarditis and other cardiovascular complications of COVID-19 mRNA-based COVID-19 vaccines <https://www.cureus.com/articles/61030-myocarditis-and-other-cardiovascular-complications-of-the-mrna-based-covid-19-vaccines>
<https://www.cureus.com/articles/61030-myocarditis-and-other-cardiovascular-complications-of-the-mrna-based-covid-19-vaccines>
94. Myocarditis, pericarditis, and cardiomyopathy after COVID-19 vaccination:
<https://pubmed.ncbi.nlm.nih.gov/34340927/>
95. Myocarditis with covid-19 mRNA vaccines:
<https://www.ahajournals.org/doi/10.1161/CIRCULATIONAHA.121.056135>

96. Association of myocarditis with COVID-19 mRNA vaccine in children:
<https://media.jamanetwork.com/news-item/association-of-myocarditis-with-mrna-covid-19-vaccine-in-children/>
97. Association of myocarditis with COVID-19 messenger RNA vaccine BNT162b2 in a case series of children:
<https://jamanetwork.com/journals/jamacardiology/fullarticle/2783052>
98. Myocarditis after immunization with COVID-19 mRNA vaccines in members of the U.S. military:
<https://jamanetwork.com/journals/jamacardiology/fullarticle/2781601%5C>
99. Myocarditis occurring after immunization with COVID-19 mRNA-based COVID-19 vaccines: <https://jamanetwork.com/journals/jamacardiology/fullarticle/2781600>
100. Myocarditis following immunization with Covid-19 mRNA:
<https://www.nejm.org/doi/full/10.1056/NEJMc2109975>
101. Patients with acute myocarditis after vaccination with COVID-19 mRNA:
<https://jamanetwork.com/journals/jamacardiology/fullarticle/2781602>
102. Myocarditis associated with vaccination with COVID-19 mRNA:
<https://pubs.rsna.org/doi/10.1148/radiol.2021211430>
103. Symptomatic Acute Myocarditis in 7 Adolescents after Pfizer-BioNTech COVID-19 Vaccination: <https://pediatrics.aappublications.org/content/148/3/e2021052478>
104. Cardiovascular magnetic resonance imaging findings in young adult patients with acute myocarditis after COVID-19 mRNA vaccination: a case series: <https://jcmr-online.biomedcentral.com/articles/10.1186/s12968-021-00795-4>
105. Clinical Guidance for Young People with Myocarditis and Pericarditis after Vaccination with COVID-19 mRNA:
<https://www.cps.ca/en/documents/position/clinical-guidance-for-youth-with-myocarditis-and-pericarditis>
106. Cardiac imaging of acute myocarditis after vaccination with COVID-19 mRNA:
<https://pubmed.ncbi.nlm.nih.gov/34402228/>
107. Case report: acute myocarditis after second dose of mRNA-1273 SARS-CoV-2 mRNA vaccine: <https://academic.oup.com/ehjcr/article/5/8/ytb319/6339567>
108. Myocarditis / pericarditis associated with COVID-19 vaccine:
https://science.gc.ca/eic/site/063.nsf/eng/h_98291.html
109. Transient cardiac injury in adolescents receiving the BNT162b2 mRNA COVID-19 vaccine:
https://journals.lww.com/pidj/Abstract/9000/Transient_Cardiac_Injury_in_Adolescents_Receiving.95800.aspx
110. Perimyocarditis in adolescents after Pfizer-BioNTech COVID-19 vaccine:
<https://academic.oup.com/jpids/advance-article/doi/10.1093/jpids/piab060/6329543>
111. The new COVID-19 mRNA vaccine platform and myocarditis: clues to the possible underlying mechanism: <https://pubmed.ncbi.nlm.nih.gov/34312010/>
112. Acute myocardial injury after COVID-19 vaccination: a case report and review of current evidence from the Vaccine Adverse Event Reporting System database:
<https://pubmed.ncbi.nlm.nih.gov/34219532/>
113. Be alert to the risk of adverse cardiovascular events after COVID-19 vaccination:
<https://www.xiahepublishing.com/m/2472-0712/ERHM-2021-00033>
114. Myocarditis associated with COVID-19 vaccination: echocardiographic, cardiac tomography, and magnetic resonance imaging findings:
<https://www.ahajournals.org/doi/10.1161/CIRCIMAGING.121.013236>
115. In-depth evaluation of a case of presumed myocarditis after the second dose of COVID-19 mRNA vaccine:
<https://www.ahajournals.org/doi/10.1161/CIRCULATIONAHA.121.056038>

116. Occurrence of acute infarct-like myocarditis after COVID-19 vaccination: just an accidental coincidence or rather a vaccination-associated autoimmune myocarditis?: <https://pubmed.ncbi.nlm.nih.gov/34333695/>
117. Recurrence of acute myocarditis temporally associated with receipt of coronavirus mRNA disease vaccine 2019 (COVID-19) in a male adolescent: <https://www.ncbi.nlm.nih.gov/pmc/articles/PMC8216855/>
118. Myocarditis after SARS-CoV-2 vaccination: a vaccine-induced reaction?: <https://pubmed.ncbi.nlm.nih.gov/34118375/>
119. Self-limited myocarditis presenting with chest pain and ST-segment elevation in adolescents after vaccination with the BNT162b2 mRNA vaccine: <https://pubmed.ncbi.nlm.nih.gov/34180390/>
120. Myopericarditis in a previously healthy adolescent male after COVID-19 vaccination: Case report: <https://pubmed.ncbi.nlm.nih.gov/34133825/>
121. Biopsy-proven lymphocytic myocarditis after first COVID-19 mRNA vaccination in a 40-year-old man: case report: <https://pubmed.ncbi.nlm.nih.gov/34487236/>
122. Insights from a murine model of COVID-19 mRNA vaccine-induced myopericarditis: could accidental intravenous injection of a vaccine induce myopericarditis? a. <https://academic.oup.com/cid/advance-article/doi/10.1093/cid/ciab741/6359059>
123. Unusual presentation of acute perimyocarditis after modern SARS-COV-2 mRNA-1273 vaccination: <https://pubmed.ncbi.nlm.nih.gov/34447639/>
124. Perimyocarditis after the first dose of mRNA-1273 SARS-CoV-2 (Modern) mRNA-1273 vaccine in a young healthy male: case report: <https://bmccardiovascdisord.biomedcentral.com/articles/10.1186/s12872-021-02183>
125. Acute myocarditis after the second dose of SARS-CoV-2 vaccine: serendipity or causal relationship: <https://pubmed.ncbi.nlm.nih.gov/34236331/>
126. Rhabdomyolysis and fasciitis induced by the COVID-19 mRNA vaccine: <https://pubmed.ncbi.nlm.nih.gov/34435250/>
127. COVID-19 vaccine-induced rhabdomyolysis: case report with literature review: <https://pubmed.ncbi.nlm.nih.gov/34186348/>.
128. GM1 ganglioside antibody and COVID-19-related Guillain Barre syndrome: case report, systemic review, and implications for vaccine development: <https://www.sciencedirect.com/science/article/pii/S2666354621000065>
129. Guillain-Barré syndrome after AstraZeneca COVID-19 vaccination: causal or casual association: <https://www.sciencedirect.com/science/article/pii/S0303846721004169>
130. Sensory Guillain-Barré syndrome after ChAdOx1 nCov-19 vaccine: report of two cases and review of the literature: <https://www.sciencedirect.com/science/article/pii/S0165572821002186>
131. Guillain-Barré syndrome after the first dose of SARS-CoV-2 vaccine: a temporary occurrence, not a causal association: <https://www.sciencedirect.com/science/article/pii/S2214250921000998>.
132. Guillain-Barré syndrome presenting as facial diplegia after vaccination with COVID-19: a case report: <https://www.sciencedirect.com/science/article/pii/S0736467921006442>
133. Guillain-Barré syndrome after the first injection of ChAdOx1 nCoV-19 vaccine: first report: <https://www.sciencedirect.com/science/article/pii/S0035378721005853>.
134. SARS-CoV-2 vaccines are not safe for those with Guillain-Barre syndrome following vaccination: <https://www.sciencedirect.com/science/article/pii/S2049080121005343>

135. Acute hyperactive encephalopathy following COVID-19 vaccination with dramatic response to methylprednisolone: a case report:
<https://www.sciencedirect.com/science/article/pii/S2049080121007536>
136. Facial nerve palsy following administration of COVID-19 mRNA vaccines: analysis of self-report database:
<https://www.sciencedirect.com/science/article/pii/S1201971221007049>
137. Neurological symptoms and neuroimaging alterations related to COVID-19 vaccine: cause or coincidence:
<https://www.sciencedirect.com/science/article/pii/S0899707121003557>.
138. New-onset refractory status epilepticus after ChAdOx1 nCoV-19 vaccination:
<https://www.sciencedirect.com/science/article/pii/S0165572821001569>
139. Acute myelitis and ChAdOx1 nCoV-19 vaccine: coincidental or causal association:
<https://www.sciencedirect.com/science/article/pii/S0165572821002137>
140. Bell's palsy and SARS-CoV-2 vaccines: an unfolding story:
<https://www.sciencedirect.com/science/article/pii/S1473309921002735>
141. Bell's palsy after the second dose of the Pfizer COVID-19 vaccine in a patient with a history of recurrent Bell's palsy:
<https://www.sciencedirect.com/science/article/pii/S266635462100020X>
142. Acute-onset central serous retinopathy after immunization with COVID-19 mRNA vaccine.: <https://www.sciencedirect.com/science/article/pii/S2451993621001456>.
143. Bell's palsy after COVID-19 vaccination: case report:
<https://www.sciencedirect.com/science/article/pii/S217358082100122X>.
144. An academic hospital experience assessing the risk of COVID-19 mRNA vaccine using patient's allergy history:
<https://www.sciencedirect.com/science/article/pii/S2213219821007972>
145. COVID-19 vaccine-induced axillary and pectoral lymphadenopathy in PET:
<https://www.sciencedirect.com/science/article/pii/S1930043321002612>
146. ANCA-associated vasculitis after Pfizer-BioNTech COVID-19 vaccine:
<https://www.sciencedirect.com/science/article/pii/S0272638621007423>
147. Late cutaneous reactions after administration of COVID-19 mRNA vaccines:
<https://www.sciencedirect.com/science/article/pii/S2213219821007996>
148. COVID-19 vaccine-induced rhabdomyolysis: case report with review of the literature: <https://www.sciencedirect.com/science/article/pii/S1871402121001880>
149. Clinical and pathologic correlates of skin reactions to COVID-19 vaccine, including V-REPP: a registry-based study:
<https://www.sciencedirect.com/science/article/pii/S0190962221024427>
150. Thrombosis with thrombocytopenia syndrome associated with COVID-19 vaccines.: <https://www.sciencedirect.com/science/article/abs/pii/S0735675721004381>.
151. COVID-19 vaccine-associated anaphylaxis: a statement from the Anaphylaxis Committee of the World Allergy Organization.:
<https://www.sciencedirect.com/science/article/pii/S1939455121000119>.
152. Cerebral venous sinus thrombosis negative for anti-PF4 antibody without thrombocytopenia after immunization with COVID-19 vaccine in an elderly, non-comorbid Indian male treated with conventional heparin-warfarin-based anticoagulation:
<https://www.sciencedirect.com/science/article/pii/S1871402121002046>.
153. Acute myocarditis after administration of BNT162b2 vaccine against COVID-19.:
<https://www.sciencedirect.com/science/article/abs/pii/S188558572100133X>
154. Blood clots and bleeding after BNT162b2 and ChAdOx1 nCoV-19 vaccine: an analysis of European data.:
<https://www.sciencedirect.com/science/article/pii/S0896841121000937>.

155. immune thrombocytopenia associated with Pfizer-BioNTech's COVID-19 BNT162b2 mRNA vaccine:
<https://www.sciencedirect.com/science/article/pii/S2214250921002018>.
156. Bullous drug eruption after the second dose of COVID-19 mRNA-1273 (Moderna) vaccine: Case report:
<https://www.sciencedirect.com/science/article/pii/S1876034121001878>.
157. COVID-19 RNA-based vaccines and the risk of prion disease:
<https://scivisionpub.com/pdfs/covid19-rna-based-vaccines-and-the-risk-of-prion-disease-1503.pdf>
158. This study notes that 115 pregnant women lost their babies, out of 827 who participated in a study on the safety of covid-19 vaccines:
<https://www.nejm.org/doi/full/10.1056/NEJMoa2104983>.
159. Process-related impurities in the ChAdOx1 nCov-19 vaccine:
<https://www.researchsquare.com/article/rs-477964/v1>
160. COVID-19 mRNA vaccine causing CNS inflammation: a case series:
<https://link.springer.com/article/10.1007/s00415-021-10780-7>
161. Allergic reactions, including anaphylaxis, after receiving the first dose of the Pfizer-BioNTech COVID-19 vaccine: <https://pubmed.ncbi.nlm.nih.gov/33475702/>
162. Allergic reactions to the first COVID-19 vaccine: a potential role of polyethylene glycol: <https://pubmed.ncbi.nlm.nih.gov/33320974/>
163. Pfizer Vaccine Raises Allergy Concerns:
<https://pubmed.ncbi.nlm.nih.gov/33384356/>
164. Allergic reactions, including anaphylaxis, after receiving the first dose of Pfizer-BioNTech COVID-19 vaccine – United States, December 14-23, 2020:
<https://pubmed.ncbi.nlm.nih.gov/33444297/>
165. Allergic reactions, including anaphylaxis, after receiving first dose of Modern COVID-19 vaccine – United States, December 21, 2020-January 10, 2021:
<https://pubmed.ncbi.nlm.nih.gov/33507892/>
166. Reports of anaphylaxis after coronavirus disease vaccination 2019, South Korea, February 26-April 30, 2021: <https://pubmed.ncbi.nlm.nih.gov/34414880/>
167. reports of anaphylaxis after receiving COVID-19 mRNA vaccines in the U.S.-Dec 14, 2020-Jan 18, 2021: <https://pubmed.ncbi.nlm.nih.gov/33576785/>
168. Immunization practices and risk of anaphylaxis: a current, comprehensive update of COVID-19 vaccination data: <https://pubmed.ncbi.nlm.nih.gov/34269740/>
169. Relationship between pre-existing allergies and anaphylactic reactions following administration of COVID-19 mRNA vaccine:
<https://pubmed.ncbi.nlm.nih.gov/34215453/>
170. Anaphylaxis Associated with COVID-19 mRNA Vaccines: Approach to Allergy Research: <https://pubmed.ncbi.nlm.nih.gov/33932618/>
171. Severe Allergic Reactions after COVID-19 Vaccination with the Pfizer / BioNTech Vaccine in Great Britain and the USA: Position Statement of the German Allergy Societies: German Medical Association of Allergologists (AeDA), German Society for Allergology and Clinical Immunology (DGAKI) and Society for Pediatric Allergology and Environmental Medicine (GPA): <https://pubmed.ncbi.nlm.nih.gov/33643776/>
172. Allergic reactions and anaphylaxis to LNP-based COVID-19 vaccines:
<https://pubmed.ncbi.nlm.nih.gov/33571463/>
173. Reported orofacial adverse effects from COVID-19 vaccines: the known and the unknown: <https://pubmed.ncbi.nlm.nih.gov/33527524/>
174. Cutaneous adverse effects of available COVID-19 vaccines:
<https://pubmed.ncbi.nlm.nih.gov/34518015/>

175. Cumulative adverse event report of anaphylaxis following injections of COVID-19 mRNA vaccine (Pfizer-BioNTech) in Japan: the first month report: <https://pubmed.ncbi.nlm.nih.gov/34347278/>
176. COVID-19 vaccines increase the risk of anaphylaxis: <https://pubmed.ncbi.nlm.nih.gov/33685103/>
177. Biphasic anaphylaxis after exposure to the first dose of the Pfizer-BioNTech COVID-19 mRNA vaccine COVID-19: <https://pubmed.ncbi.nlm.nih.gov/34050949/>
178. Allergenic components of the mRNA-1273 vaccine for COVID-19: possible involvement of polyethylene glycol and IgG-mediated complement activation: <https://pubmed.ncbi.nlm.nih.gov/33657648/>
179. Polyethylene glycol (PEG) is a cause of anaphylaxis to Pfizer / BioNTech mRNA COVID-19 vaccine: <https://pubmed.ncbi.nlm.nih.gov/33825239/>
180. Acute allergic reactions to COVID-19 mRNA vaccines: <https://pubmed.ncbi.nlm.nih.gov/33683290/>
181. Polyethylene glycole allergy of the SARS CoV2 vaccine recipient: case report of a young adult recipient and management of future exposure to SARS-CoV2: <https://pubmed.ncbi.nlm.nih.gov/33919151/>
182. Elevated rates of anaphylaxis after vaccination with Pfizer BNT162b2 mRNA vaccine against COVID-19 in Japanese healthcare workers; a secondary analysis of initial post-approval safety data: <https://pubmed.ncbi.nlm.nih.gov/34128049/>
183. Allergic reactions and adverse events associated with administration of mRNA-based vaccines. A health system experience: <https://pubmed.ncbi.nlm.nih.gov/34474708/>
184. Allergic reactions to COVID-19 vaccines: statement of the Belgian Society of Allergy and Clinical Immunology (BelSACI): <https://www.tandfonline.com/doi/abs/10.1080/17843286.2021.1909447?journalCode=yacb20>.
185. IgE-mediated allergy to polyethylene glycol (PEG) as a cause of anaphylaxis to COVID-19 mRNA vaccines: <https://pubmed.ncbi.nlm.nih.gov/34318537/>
186. Allergic reactions after COVID-19 vaccination: putting the risk in perspective: <https://pubmed.ncbi.nlm.nih.gov/34463751/>
187. Anaphylactic reactions to COVID-19 mRNA vaccines: a call for further studies: <https://pubmed.ncbi.nlm.nih.gov/33846043/> 188.
188. Risk of severe allergic reactions to COVID-19 vaccines among patients with allergic skin disease: practical recommendations. An ETFAD position statement with external experts: <https://pubmed.ncbi.nlm.nih.gov/33752263/>
189. COVID-19 vaccine and death: causality algorithm according to the WHO eligibility diagnosis: <https://pubmed.ncbi.nlm.nih.gov/34073536/>
190. Fatal brain hemorrhage after COVID-19 vaccine: <https://pubmed.ncbi.nlm.nih.gov/33928772/>
191. A case series of skin reactions to COVID-19 vaccine in the Department of Dermatology at Loma Linda University: <https://pubmed.ncbi.nlm.nih.gov/34423106/>
192. Skin reactions reported after Moderna and Pfizer's COVID-19 vaccination: a study based on a registry of 414 cases: <https://pubmed.ncbi.nlm.nih.gov/33838206/>
193. Clinical and pathologic correlates of skin reactions to COVID-19 vaccine, including V-REPP: a registry-based study: <https://pubmed.ncbi.nlm.nih.gov/34517079/>
194. Skin reactions after vaccination against SARS-COV-2: a nationwide Spanish cross-sectional study of 405 cases: <https://pubmed.ncbi.nlm.nih.gov/34254291/>

195. Varicella zoster virus and herpes simplex virus reactivation after vaccination with COVID-19: review of 40 cases in an international dermatologic registry: <https://pubmed.ncbi.nlm.nih.gov/34487581/>
196. Immune thrombosis and thrombocytopenia (VITT) associated with the COVID-19 vaccine: diagnostic and therapeutic recommendations for a new syndrome: <https://pubmed.ncbi.nlm.nih.gov/33987882/>
197. Laboratory testing for suspicion of COVID-19 vaccine-induced thrombotic (immune) thrombocytopenia: <https://pubmed.ncbi.nlm.nih.gov/34138513/>
198. Intracerebral hemorrhage due to thrombosis with thrombocytopenia syndrome after COVID-19 vaccination: the first fatal case in Korea: <https://pubmed.ncbi.nlm.nih.gov/34402235/>
199. Risk of thrombocytopenia and thromboembolism after covid-19 vaccination and positive SARS-CoV-2 tests: self-controlled case series study: <https://pubmed.ncbi.nlm.nih.gov/34446426/>
200. Vaccine-induced immune thrombotic thrombocytopenia and cerebral venous sinus thrombosis after covid-19 vaccination; a systematic review: <https://pubmed.ncbi.nlm.nih.gov/34365148/>.
201. Nerve and muscle adverse events after vaccination with COVID-19: a systematic review and meta-analysis of clinical trials: <https://pubmed.ncbi.nlm.nih.gov/34452064/>.
202. A rare case of cerebral venous thrombosis and disseminated intravascular coagulation temporally associated with administration of COVID-19 vaccine: <https://pubmed.ncbi.nlm.nih.gov/33917902/>
203. Primary adrenal insufficiency associated with thrombotic immune thrombocytopenia induced by Oxford-AstraZeneca ChAdOx1 nCoV-19 vaccine (VITT): <https://pubmed.ncbi.nlm.nih.gov/34256983/>
204. Acute cerebral venous thrombosis and pulmonary artery embolism associated with the COVID-19 vaccine: <https://pubmed.ncbi.nlm.nih.gov/34247246/>.
205. Thromboaspiration infusion and fibrinolysis for portomesenteric thrombosis after administration of AstraZeneca COVID-19 vaccine: <https://pubmed.ncbi.nlm.nih.gov/34132839/>
206. 59-year-old woman with extensive deep venous thrombosis and pulmonary thromboembolism 7 days after a first dose of Pfizer-BioNTech BNT162b2 mRNA vaccine COVID-19: <https://pubmed.ncbi.nlm.nih.gov/34117206/>
207. Oxford-AstraZeneca COVID-19 vaccine-induced cerebral venous thrombosis and thrombocytopenia: A missed opportunity for a rapid return of experience. <https://pubmed.ncbi.nlm.nih.gov/34033927/>
208. Myocarditis and other cardiovascular complications of mRNA-based COVID-19 vaccines: <https://pubmed.ncbi.nlm.nih.gov/34277198/>
209. Pericarditis after administration of COVID-19 mRNA BNT162b2 vaccine: <https://pubmed.ncbi.nlm.nih.gov/34364831/>
210. Unusual presentation of acute pericarditis after vaccination against SARS-COV-2 mRNA-1237 Moderna: <https://pubmed.ncbi.nlm.nih.gov/34447639/>
211. Case report: acute myocarditis after second dose of SARS-CoV-2 mRNA-1273 vaccine mRNA-1273: <https://pubmed.ncbi.nlm.nih.gov/34514306/>
212. Immune-mediated disease outbreaks or recent-onset disease in 27 subjects after mRNA/DNA vaccination against SARS-CoV-2: <https://pubmed.ncbi.nlm.nih.gov/33946748/>
213. Insights from a murine model of myopericarditis induced by COVID-19 mRNA vaccine: could accidental intravenous injection of a vaccine induce myopericarditis: <https://pubmed.ncbi.nlm.nih.gov/34453510/>

214. Immune thrombocytopenia in a 22-year-old post Covid-19 vaccine: <https://pubmed.ncbi.nlm.nih.gov/33476455/>
215. propylthiouracil-induced neutrophil anti-cytoplasmic antibody-associated vasculitis after COVID-19 vaccination: <https://pubmed.ncbi.nlm.nih.gov/34451967/>
216. Secondary immune thrombocytopenia (ITP) associated with ChAdOx1 Covid-19 vaccine: case report: <https://pubmed.ncbi.nlm.nih.gov/34377889/>
217. Thrombosis with thrombocytopenia syndrome (TTS) following AstraZeneca ChAdOx1 nCoV-19 (AZD1222) COVID-19 vaccination: risk-benefit analysis for persons <60 years in Australia: <https://pubmed.ncbi.nlm.nih.gov/34272095/>
218. COVID-19 vaccination association and facial nerve palsy: A case-control study: <https://pubmed.ncbi.nlm.nih.gov/34165512/>
219. The association between COVID-19 vaccination and Bell's palsy: <https://pubmed.ncbi.nlm.nih.gov/34411533/>
220. Bell's palsy after COVID-19 vaccination: <https://pubmed.ncbi.nlm.nih.gov/33611630/>
221. Acute transverse myelitis (ATM): clinical review of 43 patients with COVID-19-associated ATM and 3 serious adverse events of post-vaccination ATM with ChAdOx1 nCoV-19 vaccine (AZD1222): <https://pubmed.ncbi.nlm.nih.gov/33981305/>
222. Bell's palsy after 24 hours of mRNA-1273 SARS-CoV-2 mRNA-1273 vaccine: <https://pubmed.ncbi.nlm.nih.gov/34336436/>
223. Sequential contralateral facial nerve palsy after first and second doses of COVID-19 vaccine: <https://pubmed.ncbi.nlm.nih.gov/34281950/>.
224. Transverse myelitis induced by SARS-CoV-2 vaccination: <https://pubmed.ncbi.nlm.nih.gov/34458035/>
225. Peripheral facial nerve palsy after vaccination with BNT162b2 (COVID-19): <https://pubmed.ncbi.nlm.nih.gov/33734623/>
226. Acute abducens nerve palsy after COVID-19 vaccination: <https://pubmed.ncbi.nlm.nih.gov/34044114/>.
227. Facial nerve palsy after administration of COVID-19 mRNA vaccines: analysis of self-report database: <https://pubmed.ncbi.nlm.nih.gov/34492394/>
228. Transient oculomotor paralysis after administration of RNA-1273 messenger vaccine for SARS-CoV-2 diplopia after COVID-19 vaccine: <https://pubmed.ncbi.nlm.nih.gov/34369471/>
229. Bell's palsy after Ad26.COV2.S COVID-19 vaccination: <https://pubmed.ncbi.nlm.nih.gov/34014316/>
230. Bell's palsy after COVID-19 vaccination: case report: <https://pubmed.ncbi.nlm.nih.gov/34330676/>
231. A case of acute demyelinating polyradiculoneuropathy with bilateral facial palsy following ChAdOx1 nCoV-19 vaccination: <https://pubmed.ncbi.nlm.nih.gov/34272622/>
232. Guillian Barré syndrome after vaccination with mRNA-1273 against COVID-19: <https://pubmed.ncbi.nlm.nih.gov/34477091/>
233. Acute facial paralysis as a possible complication of SARS-CoV-2 vaccination: <https://pubmed.ncbi.nlm.nih.gov/33975372/>.
234. Bell's palsy after COVID-19 vaccination with high antibody response in CSF: <https://pubmed.ncbi.nlm.nih.gov/34322761/>.
235. Parsonage-Turner syndrome associated with SARS-CoV-2 or SARS-CoV-2 vaccination. Comment on: "Neuralgic amyotrophy and COVID-19 infection: 2 cases of accessory spinal nerve palsy" by Coll et al. Articular Spine 2021; 88: 10519: <https://pubmed.ncbi.nlm.nih.gov/34139321/>.

236. Bell's palsy after a single dose of vaccine mRNA. SARS-CoV-2: case report: <https://pubmed.ncbi.nlm.nih.gov/34032902/>.
237. Autoimmune hepatitis developing after coronavirus disease vaccine 2019 (COVID-19): causality or victim?: <https://pubmed.ncbi.nlm.nih.gov/33862041/>
238. Autoimmune hepatitis triggered by vaccination against SARS-CoV-2: <https://pubmed.ncbi.nlm.nih.gov/34332438/>
239. Acute autoimmune-like hepatitis with atypical antimitochondrial antibody after vaccination with COVID-19 mRNA: a new clinical entity: <https://pubmed.ncbi.nlm.nih.gov/34293683/>.
240. Autoimmune hepatitis after COVID vaccine: <https://pubmed.ncbi.nlm.nih.gov/34225251/>
241. A novel case of bifacial diplegia variant of Guillain-Barré syndrome after vaccination with Janssen COVID-19: <https://pubmed.ncbi.nlm.nih.gov/34449715/>
242. Comparison of vaccine-induced thrombotic events between ChAdOx1 nCoV-19 and Ad26.COV.2.S vaccines: <https://pubmed.ncbi.nlm.nih.gov/34139631/>.
243. Bilateral superior ophthalmic vein thrombosis, ischemic stroke and immune thrombocytopenia after vaccination with ChAdOx1 nCoV-19: <https://pubmed.ncbi.nlm.nih.gov/33864750/>
244. Diagnosis and treatment of cerebral venous sinus thrombosis with vaccine-induced immune-immune thrombotic thrombocytopenia: <https://pubmed.ncbi.nlm.nih.gov/33914590/>
245. Venous sinus thrombosis after vaccination with ChAdOx1 nCov-19: <https://pubmed.ncbi.nlm.nih.gov/34420802/>
246. Cerebral venous sinus thrombosis following vaccination against SARS-CoV-2: an analysis of cases reported to the European Medicines Agency: <https://pubmed.ncbi.nlm.nih.gov/34293217/>
247. Risk of thrombocytopenia and thromboembolism after covid-19 vaccination and positive SARS-CoV-2 tests: self-controlled case series study: <https://pubmed.ncbi.nlm.nih.gov/34446426/>
248. Blood clots and bleeding after BNT162b2 and ChAdOx1 nCoV-19 vaccination: an analysis of European data: <https://pubmed.ncbi.nlm.nih.gov/34174723/>
249. Arterial events, venous thromboembolism, thrombocytopenia and bleeding after vaccination with Oxford-AstraZeneca ChAdOx1-S in Denmark and Norway: population-based cohort study: <https://pubmed.ncbi.nlm.nih.gov/33952445/>
250. First dose of ChAdOx1 and BNT162b2 COVID-19 vaccines and thrombocytopenic, thromboembolic and hemorrhagic events in Scotland: <https://pubmed.ncbi.nlm.nih.gov/34108714/>
251. Cerebral venous thrombosis associated with COVID-19 vaccine in Germany: <https://pubmed.ncbi.nlm.nih.gov/34288044/>
252. Malignant cerebral infarction after vaccination with ChAdOx1 nCov-19: a catastrophic variant of vaccine-induced immune-mediated thrombotic thrombocytopenia: <https://pubmed.ncbi.nlm.nih.gov/34341358/>
253. celiac artery and splenic artery thrombosis complicated by splenic infarction 7 days after the first dose of Oxford vaccine, causal relationship or coincidence: <https://pubmed.ncbi.nlm.nih.gov/34261633/>.
254. Primary adrenal insufficiency associated with Oxford-AstraZeneca ChAdOx1 nCoV-19 (VITT) vaccine-induced immune thrombotic thrombocytopenia: <https://pubmed.ncbi.nlm.nih.gov/34256983/>
255. Thrombocytopenia after COVID-19 vaccination: <https://pubmed.ncbi.nlm.nih.gov/34332437/>.

256. Cerebral venous sinus thrombosis associated with thrombocytopenia after COVID-19 vaccination: <https://pubmed.ncbi.nlm.nih.gov/33845870/>.
257. Thrombosis with thrombocytopenia syndrome after COVID-19 immunization: <https://pubmed.ncbi.nlm.nih.gov/34236343/>
258. Acute myocardial infarction within 24 hours after COVID-19 vaccination: <https://pubmed.ncbi.nlm.nih.gov/34364657/>.
259. Bilateral acute macular neuroretinopathy after SARS-CoV-2 vaccination: <https://pubmed.ncbi.nlm.nih.gov/34287612/>
260. central venous sinus thrombosis with subarachnoid hemorrhage after COVID-19 mRNA vaccination: are these reports merely coincidental: <https://pubmed.ncbi.nlm.nih.gov/34478433/>
261. Intracerebral hemorrhage due to thrombosis with thrombocytopenia syndrome after COVID-19 vaccination: the first fatal case in Korea: <https://pubmed.ncbi.nlm.nih.gov/34402235/>
262. Cerebral venous sinus thrombosis negative for anti-PF4 antibody without thrombocytopenia after immunization with COVID-19 vaccine in a non-comorbid elderly Indian male treated with conventional heparin-warfarin-based anticoagulation: <https://pubmed.ncbi.nlm.nih.gov/34186376/> 263.
263. Cerebral venous sinus thrombosis 2 weeks after first dose of SARS-CoV-2 mRNA vaccine: <https://pubmed.ncbi.nlm.nih.gov/34101024/>
264. A case of multiple thrombocytopenia and thrombosis following vaccination with ChAdOx1 nCoV-19 against SARS-CoV-2: <https://pubmed.ncbi.nlm.nih.gov/34137813/>
265. Vaccine-induced thrombotic thrombocytopenia: the elusive link between thrombosis and adenovirus-based SARS-CoV-2 vaccines: <https://pubmed.ncbi.nlm.nih.gov/34191218/> 266.
266. Acute ischemic stroke revealing immune thrombotic thrombocytopenia induced by ChAdOx1 nCov-19 vaccine: impact on recanalization strategy: <https://pubmed.ncbi.nlm.nih.gov/34175640/>
267. New-onset refractory status epilepticus after ChAdOx1 nCoV-19 vaccine: <https://pubmed.ncbi.nlm.nih.gov/34153802/>
268. Thrombosis with thrombocytopenia syndrome associated with COVID-19 viral vector vaccines: <https://pubmed.ncbi.nlm.nih.gov/34092488/>
269. Pulmonary embolism, transient ischemic attack, and thrombocytopenia after Johnson & Johnson COVID-19 vaccine: <https://pubmed.ncbi.nlm.nih.gov/34261635/>
270. Thromboaspiration infusion and fibrinolysis for portomesenteric thrombosis after administration of the AstraZeneca COVID-19 vaccine: <https://pubmed.ncbi.nlm.nih.gov/34132839/>.
271. Spontaneous HIT syndrome: knee replacement, infection, and parallels with vaccine-induced immune thrombotic thrombocytopenia: <https://pubmed.ncbi.nlm.nih.gov/34144250/>
272. Deep venous thrombosis (DVT) occurring shortly after second dose of SARS-CoV-2 mRNA vaccine: <https://pubmed.ncbi.nlm.nih.gov/33687691/>
273. Procoagulant antibody-mediated procoagulant platelets in immune thrombotic thrombocytopenia associated with SARS-CoV-2 vaccination: <https://pubmed.ncbi.nlm.nih.gov/34011137/>.
274. Vaccine-induced immune thrombotic thrombocytopenia causing a severe form of cerebral venous thrombosis with high mortality rate: a case series: <https://pubmed.ncbi.nlm.nih.gov/34393988/>.

275. Procoagulant microparticles: a possible link between vaccine-induced immune thrombocytopenia (VITT) and cerebral sinus venous thrombosis: <https://pubmed.ncbi.nlm.nih.gov/34129181/>.
276. Atypical thrombosis associated with the vaccine VaxZevria® (AstraZeneca): data from the French network of regional pharmacovigilance centers: <https://pubmed.ncbi.nlm.nih.gov/34083026/>.
277. Acute cerebral venous thrombosis and pulmonary artery embolism associated with the COVID-19 vaccine: <https://pubmed.ncbi.nlm.nih.gov/34247246/>.
278. Vaccine-induced thrombosis and thrombocytopenia with bilateral adrenal hemorrhage: <https://pubmed.ncbi.nlm.nih.gov/34235757/>.
279. Palmar digital vein thrombosis after Oxford-AstraZeneca COVID-19 vaccination: <https://pubmed.ncbi.nlm.nih.gov/34473841/>.
280. Cutaneous thrombosis associated with cutaneous necrosis following Oxford-AstraZeneca COVID-19 vaccination: <https://pubmed.ncbi.nlm.nih.gov/34189756/>.
281. Cerebral venous thrombosis following COVID-19 vaccination: <https://pubmed.ncbi.nlm.nih.gov/34045111/>.
282. Lipschütz ulcers after AstraZeneca COVID-19 vaccination: <https://pubmed.ncbi.nlm.nih.gov/34366434/>.
283. Amyotrophic Neuralgia secondary to Vaxzevri vaccine (AstraZeneca) COVID-19: <https://pubmed.ncbi.nlm.nih.gov/34330677/>.
284. Thrombosis with thrombocytopenia after Messenger vaccine RNA-1273: <https://pubmed.ncbi.nlm.nih.gov/34181446/>.
285. Intracerebral hemorrhage twelve days after vaccination with ChAdOx1 nCoV-19: <https://pubmed.ncbi.nlm.nih.gov/34477089/>.
286. Thrombotic thrombocytopenia after vaccination with COVID-19: in search of the underlying mechanism: <https://pubmed.ncbi.nlm.nih.gov/34071883/>.
287. Coronavirus (COVID-19) Vaccine-induced immune thrombotic thrombocytopenia (VITT): <https://pubmed.ncbi.nlm.nih.gov/34033367/>.
288. Comparison of adverse drug reactions among four COVID-19 vaccines in Europe using the EudraVigilance database: Thrombosis in unusual sites: <https://pubmed.ncbi.nlm.nih.gov/34375510/>.
289. Immunoglobulin adjuvant for vaccine-induced immune thrombotic thrombocytopenia: <https://pubmed.ncbi.nlm.nih.gov/34107198/>.
290. Severe vaccine-induced thrombotic thrombocytopenia following vaccination with COVID-19: an autopsy case report and review of the literature: <https://pubmed.ncbi.nlm.nih.gov/34355379/>.
291. A case of acute pulmonary embolism after immunization with SARS-CoV-2 mRNA: <https://pubmed.ncbi.nlm.nih.gov/34452028/>.
292. Neurosurgical considerations regarding decompressive craniectomy for intracerebral hemorrhage after SARS-CoV-2 vaccination in vaccine-induced thrombotic thrombocytopenia-VITT: <https://pubmed.ncbi.nlm.nih.gov/34202817/>.
293. Thrombosis and SARS-CoV-2 vaccines: vaccine-induced immune thrombotic thrombocytopenia: <https://pubmed.ncbi.nlm.nih.gov/34237213/>.
294. Acquired thrombotic thrombocytopenic thrombocytopenic purpura: a rare disease associated with the BNT162b2 vaccine: <https://pubmed.ncbi.nlm.nih.gov/34105247/>.
295. Immune complexes, innate immunity and NETosis in ChAdOx1 vaccine-induced thrombocytopenia: <https://pubmed.ncbi.nlm.nih.gov/34405870/>.
296. Sensory Guillain-Barré syndrome following ChAdOx1 nCov-19 vaccine: report of two cases and review of the literature: <https://pubmed.ncbi.nlm.nih.gov/34416410/>.
297. Vogt-Koyanagi-Harada syndrome after COVID-19 and ChAdOx1 nCoV-19 (AZD1222) vaccination: <https://pubmed.ncbi.nlm.nih.gov/34462013/>.

298. Reactivation of Vogt-Koyanagi-Harada disease under control for more than 6 years, after anti-SARS-CoV-2 vaccination: <https://pubmed.ncbi.nlm.nih.gov/34224024/>.
299. Post-vaccinal encephalitis after ChAdOx1 nCov-19: <https://pubmed.ncbi.nlm.nih.gov/34324214/>
300. Neurological symptoms and neuroimaging alterations related to COVID-19 vaccine: cause or coincidence?: <https://pubmed.ncbi.nlm.nih.gov/34507266/>
301. Fatal systemic capillary leak syndrome after SARS-COV-2 vaccination in a patient with multiple myeloma: <https://pubmed.ncbi.nlm.nih.gov/34459725/>
302. Polyarthralgia and myalgia syndrome after vaccination with ChAdOx1 nCOV-19: <https://pubmed.ncbi.nlm.nih.gov/34463066/>
303. Three cases of subacute thyroiditis after SARS-CoV-2 vaccination: post-vaccination ASIA syndrome: <https://pubmed.ncbi.nlm.nih.gov/34043800/>.
304. Facial diplegia: a rare and atypical variant of Guillain-Barré syndrome and the Ad26.COV2.S vaccine: <https://pubmed.ncbi.nlm.nih.gov/34447646/>
305. Association between ChAdOx1 nCoV-19 vaccination and bleeding episodes: large population-based cohort study: <https://pubmed.ncbi.nlm.nih.gov/34479760/>.
306. fulminant myocarditis and systemic hyperinflammation temporally associated with BNT162b2 COVID-19 mRNA vaccination in two patients: <https://pubmed.ncbi.nlm.nih.gov/34416319/>.
307. Adverse effects reported after COVID-19 vaccination in a tertiary care hospital, centered on cerebral venous sinus thrombosis (CVST): <https://pubmed.ncbi.nlm.nih.gov/34092166/>
308. Induction and exacerbation of subacute cutaneous lupus erythematosus erythematosus after mRNA- or adenoviral vector-based SARS-CoV-2 vaccination: <https://pubmed.ncbi.nlm.nih.gov/34291477/>
309. Petechiae and peeling of fingers after immunization with BTN162b2 messenger RNA (mRNA)-based COVID-19 vaccine: <https://pubmed.ncbi.nlm.nih.gov/34513435/>
310. Hepatitis C virus reactivation after COVID-19 vaccination: a case report: <https://pubmed.ncbi.nlm.nih.gov/34512037/>
311. Bilateral immune-mediated keratolysis after immunization with SARS-CoV-2 recombinant viral vector vaccine: <https://pubmed.ncbi.nlm.nih.gov/34483273/>.
312. Immune-mediated thrombocytopenic purpura after Pfizer-BioNTech COVID-19 vaccine in an elderly woman: <https://pubmed.ncbi.nlm.nih.gov/34513446/>
313. Platelet activation and modulation in thrombosis with thrombocytopenia syndrome associated with the ChAdO × 1 nCov-19 vaccine: <https://pubmed.ncbi.nlm.nih.gov/34474550/>
314. Reactive arthritis after COVID-19 vaccination: <https://pubmed.ncbi.nlm.nih.gov/34033732/>.
315. Two cases of Graves' disease after SARS-CoV-2 vaccination: an autoimmune / inflammatory syndrome induced by adjuvants: <https://pubmed.ncbi.nlm.nih.gov/33858208/>
316. Acute relapse and impaired immunization after COVID-19 vaccination in a patient with multiple sclerosis treated with rituximab: <https://pubmed.ncbi.nlm.nih.gov/34015240/>
317. Widespread fixed bullous drug eruption after vaccination with ChAdOx1 nCoV-19: <https://pubmed.ncbi.nlm.nih.gov/34482558/>
318. COVID-19 mRNA vaccine causing CNS inflammation: a case series: <https://pubmed.ncbi.nlm.nih.gov/34480607/>
319. Thymic hyperplasia after Covid-19 mRNA-based vaccination with Covid-19: <https://pubmed.ncbi.nlm.nih.gov/34462647/>

320. Acute disseminated encephalomyelitis following vaccination against SARS-CoV-2: <https://pubmed.ncbi.nlm.nih.gov/34325334/>
321. Tolosa-Hunt syndrome occurring after COVID-19 vaccination: <https://pubmed.ncbi.nlm.nih.gov/34513398/>
322. Systemic capillary extravasation syndrome following vaccination with ChAdOx1 nCoV-19 (Oxford-AstraZeneca): <https://pubmed.ncbi.nlm.nih.gov/34362727/>
323. Immune-mediated thrombocytopenia associated with Ad26.COVS vaccine (Janssen; Johnson & Johnson): <https://pubmed.ncbi.nlm.nih.gov/34469919/>.
324. Transient thrombocytopenia with glycoprotein-specific platelet autoantibodies after vaccination with Ad26.COVS: case report: <https://pubmed.ncbi.nlm.nih.gov/34516272/>.
325. Acute hyperactive encephalopathy following COVID-19 vaccination with dramatic response to methylprednisolone: case report: <https://pubmed.ncbi.nlm.nih.gov/34512961/>
326. Transient cardiac injury in adolescents receiving the BNT162b2 mRNA COVID-19 vaccine: <https://pubmed.ncbi.nlm.nih.gov/34077949/>
327. Autoimmune hepatitis developing after ChAdOx1 nCoV-19 vaccine (Oxford-AstraZeneca): <https://pubmed.ncbi.nlm.nih.gov/34171435/>
328. Severe relapse of multiple sclerosis after COVID-19 vaccination: a case report: <https://pubmed.ncbi.nlm.nih.gov/34447349/>
329. Lymphohistocytic myocarditis after vaccination with the COVID-19 viral vector Ad26.COVS: <https://pubmed.ncbi.nlm.nih.gov/34514078/>
330. Hemophagocytic lymphohistiocytosis after vaccination with ChAdOx1 nCoV-19: <https://pubmed.ncbi.nlm.nih.gov/34406660/>.
331. IgA vasculitis in adult patient after vaccination with ChAdOx1 nCoV-19: <https://pubmed.ncbi.nlm.nih.gov/34509658/>
332. A case of leukocytoclastic vasculitis after vaccination with a SARS-CoV2 vaccine: case report: <https://pubmed.ncbi.nlm.nih.gov/34196469/>.
333. Onset / outbreak of psoriasis after Corona virus ChAdOx1 nCoV-19 vaccine (Oxford-AstraZeneca / Covishield): report of two cases: <https://pubmed.ncbi.nlm.nih.gov/34350668/>
334. Hailey-Hailey disease exacerbation after SARS-CoV-2 vaccination: <https://pubmed.ncbi.nlm.nih.gov/34436620/>
335. Supraclavicular lymphadenopathy after COVID-19 vaccination in Korea: serial follow-up by ultrasonography: <https://pubmed.ncbi.nlm.nih.gov/34116295/>.
336. COVID-19 vaccine, immune thrombotic thrombocytopenia, jaundice, hyperviscosity: concern in cases with underlying hepatic problems: <https://pubmed.ncbi.nlm.nih.gov/34509271/>.
337. Report of the International Cerebral Venous Thrombosis Consortium on cerebral venous thrombosis after SARS-CoV-2 vaccination: <https://pubmed.ncbi.nlm.nih.gov/34462996/>
338. Immune thrombocytopenia after vaccination during the COVID-19 pandemic: <https://pubmed.ncbi.nlm.nih.gov/34435486/>
339. COVID-19: lessons from the Norwegian tragedy should be taken into account in planning for vaccine launch in less developed/developing countries: <https://pubmed.ncbi.nlm.nih.gov/34435142/>
340. Rituximab-induced acute lympholysis and pancytopenia following vaccination with COVID-19: <https://pubmed.ncbi.nlm.nih.gov/34429981/>
341. Exacerbation of plaque psoriasis after COVID-19 inactivated mRNA and BNT162b2 vaccines: report of two cases: <https://pubmed.ncbi.nlm.nih.gov/34427024/>

342. Vaccine-induced interstitial lung disease: a rare reaction to COVID-19 vaccine: <https://pubmed.ncbi.nlm.nih.gov/34510014/>.
343. Vesiculobullous cutaneous reactions induced by COVID-19 mRNA vaccine: report of four cases and review of the literature: <https://pubmed.ncbi.nlm.nih.gov/34236711/>
344. Vaccine-induced thrombocytopenia with severe headache: <https://pubmed.ncbi.nlm.nih.gov/34525282/>
345. Acute perimyocarditis after the first dose of COVID-19 mRNA vaccine: <https://pubmed.ncbi.nlm.nih.gov/34515024/>
346. Rhabdomyolysis and fasciitis induced by COVID-19 mRNA vaccine: <https://pubmed.ncbi.nlm.nih.gov/34435250/>.
347. Rare cutaneous adverse effects of COVID-19 vaccines: a case series and review of the literature: <https://pubmed.ncbi.nlm.nih.gov/34363637/>
348. Immune thrombocytopenia associated with the Pfizer-BioNTech COVID-19 mRNA vaccine BNT162b2: <https://www.sciencedirect.com/science/article/pii/S2214250921002018>
349. Secondary immune thrombocytopenia putatively attributable to COVID-19 vaccination: <https://casereports.bmj.com/content/14/5/e242220.abstract>.
350. Immune thrombocytopenia following Pfizer-BioNTech BNT162b2 mRNA COVID-19 vaccine: <https://pubmed.ncbi.nlm.nih.gov/34155844/>
351. Newly diagnosed idiopathic thrombocytopenia after COVID-19 vaccine administration: <https://www.ncbi.nlm.nih.gov/pmc/articles/PMC8176657/>.
352. Idiopathic thrombocytopenic purpura and the Modern Covid-19 vaccine: [https://www.annemergmed.com/article/S0196-0644\(21\)00122-0/fulltext](https://www.annemergmed.com/article/S0196-0644(21)00122-0/fulltext).
353. Thrombocytopenia after Pfizer and Moderna SARS vaccination – CoV -2: <https://www.ncbi.nlm.nih.gov/pmc/articles/PMC8014568/>.
354. Immune thrombocytopenic purpura and acute liver injury after COVID-19 vaccination: https://casereports.bmj.com/content/14/7/e242678.full?int_source=trendmd&int_medium=cpc&int_campaign=usage-042019
355. Collection of complement-mediated and autoimmune-mediated hematologic conditions after SARS-CoV-2 vaccination: https://ashpublications.org/bloodadvances/article/5/13/2794/476324/Autoimmune-and-complement-mediated-hematologic?utm_source=TrendMD&utm_medium=cpc&utm_campaign=Blood_Advances_TrendMD_1.
356. Petechial rash associated with CoronaVac vaccination: first report of cutaneous side effects before phase 3 results: https://ejhp.bmj.com/content/early/2021/05/23/ejhpharm-2021-002794?int_source=trendmd&int_medium=cpc&int_campaign=usage-042019
357. COVID-19 vaccines induce severe hemolysis in paroxysmal nocturnal hemoglobinuria: <https://ashpublications.org/blood/article/137/26/3670/475905/COVID-19-vaccines- induce-severe-hemolysis-in>
358. Cerebral venous thrombosis associated with COVID-19 vaccine in Germany: <https://pubmed.ncbi.nlm.nih.gov/34288044/>.
359. Cerebral venous sinus thrombosis after COVID-19 vaccination : Neurological and radiological management: <https://pubmed.ncbi.nlm.nih.gov/34327553/>.
360. Cerebral venous thrombosis and thrombocytopenia after COVID-19 vaccination: <https://pubmed.ncbi.nlm.nih.gov/33878469/>.
361. Cerebral venous sinus thrombosis and thrombocytopenia after COVID-19 vaccination: report of two cases in the United Kingdom: <https://pubmed.ncbi.nlm.nih.gov/33857630/>.

362. Cerebral venous thrombosis induced by SARS-CoV-2 vaccine: <https://pubmed.ncbi.nlm.nih.gov/34090750/>.
363. Carotid artery immune thrombosis induced by adenovirus-vectored COVID-19 vaccine: case report: <https://pubmed.ncbi.nlm.nih.gov/34312301/>.
364. Cerebral venous sinus thrombosis associated with vaccine-induced thrombotic thrombocytopenia: <https://pubmed.ncbi.nlm.nih.gov/34333995/>
365. The roles of platelets in COVID-19-associated coagulopathy and vaccine-induced immune-immune thrombotic thrombocytopenia: <https://pubmed.ncbi.nlm.nih.gov/34455073/>
366. Cerebral venous thrombosis after the BNT162b2 mRNA SARS-CoV-2 vaccine: <https://pubmed.ncbi.nlm.nih.gov/34111775/>.
367. Cerebral venous thrombosis after COVID-19 vaccination: <https://pubmed.ncbi.nlm.nih.gov/34045111/>
368. Lethal cerebral venous sinus thrombosis after COVID-19 vaccination: <https://pubmed.ncbi.nlm.nih.gov/33983464/>
369. Cerebral venous sinus thrombosis in the U.S. population, After SARS-CoV-2 vaccination with adenovirus and after COVID-19: <https://pubmed.ncbi.nlm.nih.gov/34116145/>
370. Cerebral venous thrombosis after COVID-19 vaccination: is the risk of thrombosis increased by intravascular administration of the vaccine: <https://pubmed.ncbi.nlm.nih.gov/34286453/>.
371. Central venous sinus thrombosis with subarachnoid hemorrhage after COVID-19 mRNA vaccination: are these reports merely coincidental: <https://pubmed.ncbi.nlm.nih.gov/34478433/>
372. Cerebral venous sinus thrombosis after ChAdOx1 nCov-19 vaccination with a misleading first brain MRI: <https://pubmed.ncbi.nlm.nih.gov/34244448/>
373. Early results of bivalirudin treatment for thrombotic thrombocytopenia and cerebral venous sinus thrombosis after vaccination with Ad26.COV2.S: <https://pubmed.ncbi.nlm.nih.gov/34226070/>
374. Cerebral venous sinus thrombosis associated with post-vaccination thrombocytopenia by COVID-19: <https://pubmed.ncbi.nlm.nih.gov/33845870/>.
375. Cerebral venous sinus thrombosis 2 weeks after the first dose of SARS-CoV-2 mRNA vaccine: <https://pubmed.ncbi.nlm.nih.gov/34101024/>.
376. Vaccine-induced immune thrombotic thrombocytopenia causing a severe form of cerebral venous thrombosis with a high mortality rate: a case series: <https://pubmed.ncbi.nlm.nih.gov/34393988/>.
377. Adenovirus interactions with platelets and coagulation and vaccine-associated autoimmune thrombocytopenia thrombosis syndrome: <https://pubmed.ncbi.nlm.nih.gov/34407607/>.
378. Headache attributed to COVID-19 (SARS-CoV-2 coronavirus) vaccination with the ChAdOx1 nCoV-19 (AZD1222) vaccine: a multicenter observational cohort study: <https://pubmed.ncbi.nlm.nih.gov/34313952/>
379. Adverse effects reported after COVID-19 vaccination in a tertiary care hospital, focus on cerebral venous sinus thrombosis (CVST): <https://pubmed.ncbi.nlm.nih.gov/34092166/>
380. Cerebral venous sinus thrombosis following vaccination against SARS-CoV-2: an analysis of cases reported to the European Medicines Agency: <https://pubmed.ncbi.nlm.nih.gov/34293217/>
381. A rare case of a middle-age Asian male with cerebral venous thrombosis after COVID-19 AstraZeneca vaccination: <https://pubmed.ncbi.nlm.nih.gov/34274191/>

382. Cerebral venous sinus thrombosis negative for anti-PF4 antibody without thrombocytopenia after immunization with COVID-19 vaccine in a non-comorbid elderly Indian male treated with conventional heparin-warfarin-based anticoagulation: <https://pubmed.ncbi.nlm.nih.gov/34186376/>
383. Arterial events, venous thromboembolism, thrombocytopenia and bleeding after vaccination with Oxford-AstraZeneca ChAdOx1-S in Denmark and Norway: population-based cohort study: <https://pubmed.ncbi.nlm.nih.gov/33952445/>
384. Procoagulant microparticles: a possible link between vaccine-induced immune thrombocytopenia (VITT) and cerebral sinus venous thrombosis: <https://pubmed.ncbi.nlm.nih.gov/34129181/>
385. U.S. case reports of cerebral venous sinus thrombosis with thrombocytopenia after vaccination with Ad26.COV2.S, March 2-April 21, 2021: <https://pubmed.ncbi.nlm.nih.gov/33929487/>.
386. Malignant cerebral infarction after vaccination with ChAdOx1 nCov-19: a catastrophic variant of vaccine-induced immune-mediated thrombotic thrombocytopenia: <https://pubmed.ncbi.nlm.nih.gov/34341358/>
387. Acute ischemic stroke revealing immune thrombotic thrombocytopenia induced by ChAdOx1 nCov-19 vaccine: impact on recanalization strategy: <https://pubmed.ncbi.nlm.nih.gov/34175640/>
388. Vaccine-induced immune thrombotic immune thrombocytopenia (VITT): a new clinicopathologic entity with heterogeneous clinical presentations: <https://pubmed.ncbi.nlm.nih.gov/34159588/>.
389. Imaging and hematologic findings in thrombosis and thrombocytopenia after vaccination with ChAdOx1 nCoV-19 (AstraZeneca): <https://pubmed.ncbi.nlm.nih.gov/34402666/>
390. Autoimmunity roots of thrombotic events after vaccination with COVID-19: <https://pubmed.ncbi.nlm.nih.gov/34508917/>
391. Cerebral venous sinus thrombosis after vaccination: the UK experience: <https://pubmed.ncbi.nlm.nih.gov/34370974/>
392. Massive cerebral venous thrombosis and venous basin infarction as late complications of COVID-19: a case report: <https://pubmed.ncbi.nlm.nih.gov/34373991/>
393. Australian and New Zealand approach to the diagnosis and treatment of vaccine-induced immune thrombosis and immune thrombocytopenia: <https://pubmed.ncbi.nlm.nih.gov/34490632/>
394. An observational study to identify the prevalence of thrombocytopenia and anti-PF4 / polyanion antibodies in Norwegian health care workers after COVID-19 vaccination: <https://pubmed.ncbi.nlm.nih.gov/33909350/>
395. Acute transverse myelitis (ATM): clinical review of 43 patients with COVID-19-associated ATM and 3 serious adverse events of post-vaccination ATM with ChAdOx1 nCoV-19 (AZD1222) vaccine: <https://pubmed.ncbi.nlm.nih.gov/33981305/>.
396. A case of acute demyelinating polyradiculoneuropathy with bilateral facial palsy after ChAdOx1 nCoV-19 vaccine.: <https://pubmed.ncbi.nlm.nih.gov/34272622/>
397. Thrombocytopenia with acute ischemic stroke and hemorrhage in a patient recently vaccinated with an adenoviral vector-based COVID-19 vaccine.: <https://pubmed.ncbi.nlm.nih.gov/33877737/>
398. Predicted and observed incidence of thromboembolic events among Koreans vaccinated with the ChAdOx1 nCoV-19 vaccine: <https://pubmed.ncbi.nlm.nih.gov/34254476/>

399. First dose of ChAdOx1 and BNT162b2 COVID-19 vaccines and thrombocytopenic, thromboembolic, and hemorrhagic events in Scotland: <https://pubmed.ncbi.nlm.nih.gov/34108714/>
400. ChAdOx1 nCoV-19 vaccine-associated thrombocytopenia: three cases of immune thrombocytopenia after 107,720 doses of ChAdOx1 vaccination in Thailand: <https://pubmed.ncbi.nlm.nih.gov/34483267/>.
401. Pulmonary embolism, transient ischemic attack, and thrombocytopenia after Johnson & Johnson COVID-19 vaccine: <https://pubmed.ncbi.nlm.nih.gov/34261635/>
402. Neurosurgical considerations with respect to decompressive craniectomy for intracerebral hemorrhage after SARS-CoV-2 vaccination in vaccine-induced thrombotic thrombocytopenia-VITT: <https://pubmed.ncbi.nlm.nih.gov/34202817/>
403. Large hemorrhagic stroke after vaccination against ChAdOx1 nCoV-19: a case report: <https://pubmed.ncbi.nlm.nih.gov/34273119/>
404. Polyarthralgia and myalgia syndrome after vaccination with ChAdOx1 nCoV-19: <https://pubmed.ncbi.nlm.nih.gov/34463066/>
405. A rare case of thrombosis and thrombocytopenia of the superior ophthalmic vein after ChAdOx1 nCoV-19 vaccination against SARS-CoV-2: <https://pubmed.ncbi.nlm.nih.gov/34276917/>
406. Thrombosis and severe acute respiratory syndrome Coronavirus 2 vaccines: vaccine-induced immune thrombotic thrombocytopenia: <https://pubmed.ncbi.nlm.nih.gov/34237213/>.
407. Renal vein thrombosis and pulmonary embolism secondary to vaccine-induced thrombotic immune thrombocytopenia (VITT): <https://pubmed.ncbi.nlm.nih.gov/34268278/>.
408. Limb ischemia and pulmonary artery thrombosis after ChAdOx1 nCoV-19 vaccine (Oxford-AstraZeneca): a case of vaccine-induced immune thrombotic thrombocytopenia: <https://pubmed.ncbi.nlm.nih.gov/33990339/>.
409. Association between ChAdOx1 nCoV-19 vaccination and bleeding episodes: large population-based cohort study: <https://pubmed.ncbi.nlm.nih.gov/34479760/>.
410. Secondary thrombocytopenia after SARS-CoV-2 vaccination: case report of hemorrhage and hematoma after minor oral surgery: <https://pubmed.ncbi.nlm.nih.gov/34314875/>.
411. Venous thromboembolism and mild thrombocytopenia after vaccination with ChAdOx1 nCoV-19: <https://pubmed.ncbi.nlm.nih.gov/34384129/>
412. Fatal exacerbation of ChAdOx1-nCoV-19-induced thrombotic thrombocytopenia syndrome after successful initial therapy with intravenous immunoglobulins: a rationale for monitoring immunoglobulin G levels: <https://pubmed.ncbi.nlm.nih.gov/34382387/>
413. A case of ANCA-associated vasculitis after AZD1222 (Oxford-AstraZeneca) SARS-CoV-2 vaccination: victim or causality?: <https://pubmed.ncbi.nlm.nih.gov/34416184/>.
414. Intracerebral hemorrhage associated with vaccine-induced thrombotic thrombocytopenia after ChAdOx1 nCOVID-19 vaccination in a pregnant woman: <https://pubmed.ncbi.nlm.nih.gov/34261297/>
415. Massive cerebral venous thrombosis due to vaccine-induced immune thrombotic thrombocytopenia: <https://pubmed.ncbi.nlm.nih.gov/34261296/>
416. Nephrotic syndrome after ChAdOx1 nCoV-19 vaccine against SARS-CoV-2: <https://pubmed.ncbi.nlm.nih.gov/34250318/>.
417. A case of vaccine-induced immune-immune thrombotic thrombocytopenia with massive arteriovenous thrombosis: <https://pubmed.ncbi.nlm.nih.gov/34059191/>

418. Cutaneous thrombosis associated with cutaneous necrosis following Oxford-AstraZeneca COVID-19 vaccination: <https://pubmed.ncbi.nlm.nih.gov/34189756/>
419. Thrombocytopenia in an adolescent with sickle cell anemia after COVID-19 vaccination: <https://pubmed.ncbi.nlm.nih.gov/34331506/>
420. Vaccine-induced thrombocytopenia with severe headache: <https://pubmed.ncbi.nlm.nih.gov/34525282/>
421. Myocarditis associated with SARS-CoV-2 mRNA vaccination in children aged 12 to 17 years: stratified analysis of a national database: <https://www.medrxiv.org/content/10.1101/2021.08.30.21262866v1>
422. COVID-19 mRNA vaccination and development of CMR-confirmed myopericarditis: <https://www.medrxiv.org/content/10.1101/2021.09.13.21262182v1.full?s=09>.
423. Severe autoimmune hemolytic anemia after receipt of SARS-CoV-2 mRNA vaccine: <https://onlinelibrary.wiley.com/doi/10.1111/trf.16672>
424. Intravenous injection of coronavirus disease 2019 (COVID-19) mRNA vaccine can induce acute myopericarditis in a mouse model: <https://t.co/j0IEM8cMXI>
425. A report of myocarditis adverse events in the U.S. Vaccine Adverse Event Reporting System. (VAERS) in association with COVID-19 injectable biologics: <https://pubmed.ncbi.nlm.nih.gov/34601006/>
426. This study concludes that: “The vaccine was associated with an excess risk of myocarditis (1 to 5 events per 100,000 persons). The risk of this potentially serious adverse event and of many other serious adverse events increased substantially after SARS-CoV-2 infection”:
https://www.nejm.org/doi/full/10.1056/NEJMoa2110475?query=featured_home
427. Bilateral uveitis after inoculation with COVID-19 vaccine: a case report: <https://www.sciencedirect.com/science/article/pii/S1201971221007797>
428. Myocarditis associated with SARS-CoV-2 mRNA vaccination in children aged 12 to 17 years: stratified analysis of a national database: <https://www.medrxiv.org/content/10.1101/2021.08.30.21262866v1>.
429. Immune-mediated hepatitis with the Moderna vaccine is no longer a coincidence but confirmed: <https://www.sciencedirect.com/science/article/pii/S0168827821020936>
430. Extensive investigations revealed consistent pathophysiologic alterations after vaccination with COVID-19 vaccines: <https://www.nature.com/articles/s41421-021-00329-3>
431. Lobar hemorrhage with ventricular rupture shortly after the first dose of an mRNA-based SARS-CoV-2 vaccine: <https://www.ncbi.nlm.nih.gov/labs/pmc/articles/PMC8553377/>
432. Mrna COVID vaccines dramatically increase endothelial inflammatory markers and risk of Acute Coronary Syndrome as measured by PULS cardiac testing: a caution: https://www.ahajournals.org/doi/10.1161/circ.144.suppl_1.10712
433. ChAdOx1 interacts with CAR and PF4 with implications for thrombosis with thrombocytopenia syndrome: <https://www.science.org/doi/10.1126/sciadv.abl8213>
434. Lethal vaccine-induced immune thrombotic immune thrombocytopenia (VITT) following announcement 26.COV2.S: first documented case outside the U.S.: <https://pubmed.ncbi.nlm.nih.gov/34626338/>
435. A prothrombotic thrombocytopenic disorder resembling heparin-induced thrombocytopenia after coronavirus-19 vaccination: <https://europepmc.org/article/PPR/PPR304469> 435.
436. VITT (vaccine-induced immune thrombotic thrombocytopenia) after vaccination with ChAdOx1 nCoV-19: <https://pubmed.ncbi.nlm.nih.gov/34731555/>

437. Vaccine-induced immune thrombotic thrombocytopenia (VITT): a new clinicopathologic entity with heterogeneous clinical presentations: <https://pubmed.ncbi.nlm.nih.gov/34159588/>
438. Treatment of acute ischemic stroke associated with ChAdOx1 nCoV-19 vaccine-induced immune thrombotic thrombocytopenia: <https://pubmed.ncbi.nlm.nih.gov/34461442/>
439. Spectrum of neurological complications after COVID-19 vaccination: <https://pubmed.ncbi.nlm.nih.gov/34719776/>.
440. Cerebral venous sinus thrombosis after vaccination: the UK experience: <https://pubmed.ncbi.nlm.nih.gov/34370974/>
441. Cerebral venous vein/venous sinus thrombosis with thrombocytopenia syndrome after COVID-19 vaccination: <https://pubmed.ncbi.nlm.nih.gov/34373413/>
442. Portal vein thrombosis due to vaccine-induced immune thrombotic immune thrombocytopenia (VITT) after Covid vaccination with ChAdOx1 nCoV-19: <https://pubmed.ncbi.nlm.nih.gov/34598301/>
443. Hematuria, a generalized petechial rash and headaches after Oxford AstraZeneca ChAdOx1 nCoV-19 vaccination: <https://pubmed.ncbi.nlm.nih.gov/34620638/>
444. Myocardial infarction and azygos vein thrombosis after vaccination with ChAdOx1 nCoV-19 in a hemodialysis patient: <https://pubmed.ncbi.nlm.nih.gov/34650896/>
445. Takotsubo (stress) cardiomyopathy after vaccination with ChAdOx1 nCoV-19: <https://pubmed.ncbi.nlm.nih.gov/34625447/>
446. Humoral response induced by Prime-Boost vaccination with ChAdOx1 nCoV-19 and BNT162b2 mRNA vaccines in a patient with multiple sclerosis treated with teriflunomide: <https://pubmed.ncbi.nlm.nih.gov/34696248/>
447. Guillain-Barré syndrome after ChAdOx1 nCoV-19 COVID-19 vaccination: a case series: <https://pubmed.ncbi.nlm.nih.gov/34548920/>
448. Refractory vaccine-induced immune thrombotic thrombocytopenia (VITT) treated with delayed therapeutic plasma exchange (TPE): <https://pubmed.ncbi.nlm.nih.gov/34672380/>.
449. Rare case of COVID-19 vaccine-associated intracranial hemorrhage with venous sinus thrombosis: <https://pubmed.ncbi.nlm.nih.gov/34556531/>.
450. Delayed headache after COVID-19 vaccination: a warning sign for vaccine-induced cerebral venous thrombosis: <https://pubmed.ncbi.nlm.nih.gov/34535076/>.
451. Clinical features of vaccine-induced thrombocytopenia and immune thrombosis: <https://pubmed.ncbi.nlm.nih.gov/34379914/>.
452. Predictors of mortality in thrombotic thrombocytopenia after adenoviral COVID-19 vaccination: the FAPIC score: <https://pubmed.ncbi.nlm.nih.gov/34545400/>
453. Ischemic stroke as a presenting feature of immune thrombotic thrombocytopenia induced by ChAdOx1-nCoV-19 vaccination: <https://pubmed.ncbi.nlm.nih.gov/34035134/>
454. In-hospital observational study of neurological disorders in patients recently vaccinated with COVID-19 mRNA vaccines: <https://pubmed.ncbi.nlm.nih.gov/34688190/>
455. Endovascular treatment for vaccine-induced cerebral venous sinus thrombosis and thrombocytopenia after vaccination with ChAdOx1 nCoV-19: report of three cases: <https://pubmed.ncbi.nlm.nih.gov/34782400/>
456. Cardiovascular, neurological, and pulmonary events after vaccination with BNT162b2, ChAdOx1 nCoV-19, and Ad26.COV2.S vaccines: an analysis of European data: <https://pubmed.ncbi.nlm.nih.gov/34710832/>
457. Cerebral venous thrombosis developing after COVID-19 vaccination: COVID-19: VITT, VATT, TTS and more: <https://pubmed.ncbi.nlm.nih.gov/34695859/>

458. Cerebral venous thrombosis and myeloproliferative neoplasms: a three-center study of 74 consecutive cases: <https://pubmed.ncbi.nlm.nih.gov/34453762/>.
459. Possible triggers of thrombocytopenia and/or hemorrhage by BNT162b2 vaccine, Pfizer-BioNTech: <https://pubmed.ncbi.nlm.nih.gov/34660652/>.
460. Multiple sites of arterial thrombosis in a 35-year-old patient after vaccination with ChAdOx1 (AstraZeneca), which required emergency femoral and carotid surgical thrombectomy: <https://pubmed.ncbi.nlm.nih.gov/34644642/>
461. Case series of vaccine-induced thrombotic thrombocytopenia in a London teaching hospital: <https://pubmed.ncbi.nlm.nih.gov/34694650/>
462. Neuro-ophthalmic complications with thrombocytopenia and thrombosis induced by ChAdOx1 nCoV-19 vaccine: <https://pubmed.ncbi.nlm.nih.gov/34726934/>
463. Thrombotic events after COVID-19 vaccination in over 50 years of age: results of a population-based study in Italy: <https://pubmed.ncbi.nlm.nih.gov/34835237/>
464. Intracerebral hemorrhage associated with vaccine-induced thrombotic thrombocytopenia after ChAdOx1 nCOVID-19 vaccination in a pregnant woman: <https://pubmed.ncbi.nlm.nih.gov/34261297/>
465. Age- and sex-specific incidence of cerebral venous sinus thrombosis associated with Ad26.COV2.S COVID-19 vaccination: <https://pubmed.ncbi.nlm.nih.gov/34724036/>.
466. Genital necrosis with cutaneous thrombosis following vaccination with COVID-19 mRNA: <https://pubmed.ncbi.nlm.nih.gov/34839563/>
467. Cerebral venous sinus thrombosis after mRNA-based COVID-19 vaccination: <https://pubmed.ncbi.nlm.nih.gov/34783932/>.
468. COVID-19 vaccine-induced immune thrombosis with thrombocytopenia thrombosis (VITT) and shades of gray in thrombus formation: <https://pubmed.ncbi.nlm.nih.gov/34624910/>
469. Inflammatory myositis after vaccination with ChAdOx1: <https://pubmed.ncbi.nlm.nih.gov/34585145/>
470. Acute ST-segment elevation myocardial infarction secondary to vaccine-induced immune thrombosis with thrombocytopenia (VITT): <https://pubmed.ncbi.nlm.nih.gov/34580132/>.
471. A rare case of COVID-19 vaccine-induced thrombotic thrombocytopenia (VITT) affecting the venosplanchnic and pulmonary arterial circulation from a UK district general hospital: <https://pubmed.ncbi.nlm.nih.gov/34535492/>
472. COVID-19 vaccine-induced thrombotic thrombocytopenia: a case series: <https://pubmed.ncbi.nlm.nih.gov/34527501/>
473. Thrombosis with Thrombocytopenia Syndrome (TTS) following AstraZeneca ChAdOx1 nCoV-19 (AZD1222) COVID-19 vaccination - A risk-benefit analysis for people < 60 years in Australia: <https://pubmed.ncbi.nlm.nih.gov/34272095/>
474. Immune thrombocytopenia after immunization with Vaxzevria ChadOx1-S vaccine (AstraZeneca), Victoria, Australia: <https://pubmed.ncbi.nlm.nih.gov/34756770/>
475. Characteristics and outcomes of patients with cerebral venous sinus thrombosis in thrombotic immune thrombocytopenia induced by SARS-CoV-2 vaccine: <https://jamanetwork.com/journals/jamaneurology/fullarticle/2784622>
476. Case study of thrombosis and thrombocytopenia syndrome after administration of the AstraZeneca COVID-19 vaccine: <https://pubmed.ncbi.nlm.nih.gov/34781321/>
477. Thrombosis with Thrombocytopenia Syndrome Associated with COVID-19 Vaccines: <https://pubmed.ncbi.nlm.nih.gov/34062319/>
478. Cerebral venous sinus thrombosis following vaccination with ChAdOx1: the first case of definite thrombosis with thrombocytopenia syndrome in India: <https://pubmed.ncbi.nlm.nih.gov/34706921/>

479. COVID-19 vaccine-associated thrombosis with thrombocytopenia syndrome (TTS): systematic review and post hoc analysis: <https://pubmed.ncbi.nlm.nih.gov/34698582/>.
480. Case report of immune thrombocytopenia after vaccination with ChAdOx1 nCoV-19: <https://pubmed.ncbi.nlm.nih.gov/34751013/>.
481. Acute transverse myelitis after COVID-19 vaccination: <https://pubmed.ncbi.nlm.nih.gov/34684047/>.
482. Concerns for adverse effects of thrombocytopenia and thrombosis after adenovirus-vectored COVID-19 vaccination: <https://pubmed.ncbi.nlm.nih.gov/34541935/>.
483. Major hemorrhagic stroke after ChAdOx1 nCoV-19 vaccination: a case report: <https://pubmed.ncbi.nlm.nih.gov/34273119/>.
484. Cerebral venous sinus thrombosis after COVID-19 vaccination: neurologic and radiologic management: <https://pubmed.ncbi.nlm.nih.gov/34327553/>.
485. Thrombocytopenia with acute ischemic stroke and hemorrhage in a patient recently vaccinated with an adenoviral vector-based COVID-19 vaccine: <https://pubmed.ncbi.nlm.nih.gov/33877737/>.
486. Intracerebral hemorrhage and thrombocytopenia after AstraZeneca COVID-19 vaccine: clinical and diagnostic challenges of vaccine-induced thrombotic thrombocytopenia: <https://pubmed.ncbi.nlm.nih.gov/34646685/>.
487. Minimal change disease with severe acute kidney injury after Oxford-AstraZeneca COVID-19 vaccine: case report: <https://pubmed.ncbi.nlm.nih.gov/34242687/>.
488. Case report: cerebral sinus vein thrombosis in two patients with AstraZeneca SARS-CoV-2 vaccine: <https://pubmed.ncbi.nlm.nih.gov/34609603/>.
489. Case report: Pityriasis rosea-like rash after vaccination with COVID-19: <https://pubmed.ncbi.nlm.nih.gov/34557507/>.
490. Extensive longitudinal transverse myelitis after ChAdOx1 nCoV-19 vaccine: case report: <https://pubmed.ncbi.nlm.nih.gov/34641797/>.
491. Acute eosinophilic pneumonia associated with anti-COVID-19 vaccine AZD1222: <https://pubmed.ncbi.nlm.nih.gov/34812326/>.
492. Thrombocytopenia, including immune thrombocytopenia after receiving COVID-19 mRNA vaccines reported to the Vaccine Adverse Event Reporting System (VAERS): <https://pubmed.ncbi.nlm.nih.gov/34006408/>.
493. A case of ANCA-associated vasculitis after AZD1222 (Oxford-AstraZeneca) SARS-CoV-2 vaccination: victim or causality?: <https://pubmed.ncbi.nlm.nih.gov/34416184/>.
494. Vaccine-induced immune thrombosis and thrombocytopenia syndrome after adenovirus-vectored severe acute respiratory syndrome coronavirus 2 vaccination: a new hypothesis on mechanisms and implications for future vaccine development: <https://pubmed.ncbi.nlm.nih.gov/34664303/>.
495. Thrombosis in peripheral artery disease and thrombotic thrombocytopenia following adenoviral COVID-19 vaccination: <https://pubmed.ncbi.nlm.nih.gov/34649281/>.
496. Newly diagnosed immune thrombocytopenia in a pregnant patient after coronavirus disease 2019 vaccination: <https://pubmed.ncbi.nlm.nih.gov/34420249/>.
497. Cerebral venous sinus thrombosis and thrombotic events after vector-based COVID-19 vaccines: systematic review and meta-analysis: <https://pubmed.ncbi.nlm.nih.gov/34610990/>.
498. Sweet's syndrome after Oxford-AstraZeneca COVID-19 vaccine (AZD1222) in an elderly woman: <https://pubmed.ncbi.nlm.nih.gov/34590397/>.
499. Sudden sensorineural hearing loss after COVID-19 vaccination: <https://pubmed.ncbi.nlm.nih.gov/34670143/>.

500. Prevalence of serious adverse events among health care professionals after receiving the first dose of ChAdOx1 nCoV-19 coronavirus vaccine (Covishield) in Togo, March 2021: <https://pubmed.ncbi.nlm.nih.gov/34819146/>.
501. Acute hemichorea-hemiballismus after COVID-19 (AZD1222) vaccination: <https://pubmed.ncbi.nlm.nih.gov/34581453/>
502. Recurrence of alopecia areata after covid-19 vaccination: a report of three cases in Italy: <https://pubmed.ncbi.nlm.nih.gov/34741583/>
503. Shingles-like skin lesion after vaccination with AstraZeneca for COVID-19: a case report: <https://pubmed.ncbi.nlm.nih.gov/34631069/>
504. Thrombosis after COVID-19 vaccination: possible link to ACE pathways: <https://pubmed.ncbi.nlm.nih.gov/34479129/>
505. Thrombocytopenia in an adolescent with sickle cell anemia after COVID-19 vaccination: <https://pubmed.ncbi.nlm.nih.gov/34331506/>
506. Leukocytoclastic vasculitis as a cutaneous manifestation of ChAdOx1 corona virus vaccine nCoV-19 (recombinant): <https://pubmed.ncbi.nlm.nih.gov/34546608/>
507. Abdominal pain and bilateral adrenal hemorrhage from immune thrombotic thrombocytopenia induced by COVID-19 vaccine: <https://pubmed.ncbi.nlm.nih.gov/34546343/>
508. Longitudinally extensive cervical myelitis after vaccination with inactivated virus based COVID-19 vaccine: <https://pubmed.ncbi.nlm.nih.gov/34849183/>
509. Induction of cutaneous leukocytoclastic vasculitis after ChAdOx1 nCoV-19 vaccine: <https://pubmed.ncbi.nlm.nih.gov/34853744/>.
510. A case of toxic epidermal necrolysis after vaccination with ChAdOx1 nCoV-19 (AZD1222): <https://pubmed.ncbi.nlm.nih.gov/34751429/>.
511. Ocular adverse events following COVID-19 vaccination: <https://pubmed.ncbi.nlm.nih.gov/34559576/>
512. Depression after ChAdOx1-S / nCoV-19 vaccination: <https://pubmed.ncbi.nlm.nih.gov/34608345/>.
513. Venous thromboembolism and mild thrombocytopenia after ChAdOx1 nCoV-19 vaccination: <https://pubmed.ncbi.nlm.nih.gov/34384129/>.
514. Recurrent ANCA-associated vasculitis after Oxford AstraZeneca ChAdOx1-S COVID-19 vaccination: a case series of two patients: <https://pubmed.ncbi.nlm.nih.gov/34755433/>
515. Major artery thrombosis and vaccination against ChAdOx1 nCov-19: <https://pubmed.ncbi.nlm.nih.gov/34839830/>
516. Rare case of contralateral supraclavicular lymphadenopathy after vaccination with COVID-19: computed tomography and ultrasound findings: <https://pubmed.ncbi.nlm.nih.gov/34667486/>
517. Cutaneous lymphocytic vasculitis after administration of the second dose of AZD1222 (Oxford-AstraZeneca) Severe acute respiratory syndrome Coronavirus 2 vaccine: chance or causality: <https://pubmed.ncbi.nlm.nih.gov/34726187/>.
518. Pancreas allograft rejection after ChAdOx1 nCoV-19 vaccine: <https://pubmed.ncbi.nlm.nih.gov/34781027/>
519. Understanding the risk of thrombosis with thrombocytopenia syndrome following Ad26.COV2.S vaccination: <https://pubmed.ncbi.nlm.nih.gov/34595694/>
520. Cutaneous adverse reactions of 35,229 doses of COVID-19 Sinovac and AstraZeneca vaccine COVID-19: a prospective cohort study in health care workers: <https://pubmed.ncbi.nlm.nih.gov/34661934/>
521. Comments on thrombosis after vaccination: spike protein leader sequence could be responsible for thrombosis and antibody-mediated thrombocytopenia: <https://pubmed.ncbi.nlm.nih.gov/34788138/>

522. Eosinophilic dermatosis after AstraZeneca COVID-19 vaccination: <https://pubmed.ncbi.nlm.nih.gov/34753210/>.
523. Severe immune thrombocytopenia following COVID-19 vaccination: report of four cases and review of the literature: <https://pubmed.ncbi.nlm.nih.gov/34653943/>.
524. Relapse of immune thrombocytopenia after COVID-19 vaccination: <https://pubmed.ncbi.nlm.nih.gov/34591991/>
525. Thrombosis in pre- and post-vaccination phase of COVID-19; <https://pubmed.ncbi.nlm.nih.gov/34650382/>
526. A look at the role of postmortem immunohistochemistry in understanding the inflammatory pathophysiology of COVID-19 disease and vaccine-related thrombotic adverse events: a narrative review: <https://pubmed.ncbi.nlm.nih.gov/34769454/>
527. COVID-19 vaccine in patients with hypercoagulability disorders: a clinical perspective: <https://pubmed.ncbi.nlm.nih.gov/34786893/>
528. Vaccine-associated thrombocytopenia and thrombosis: venous endotheliopathy leading to combined venous micro-macrothrombosis: <https://pubmed.ncbi.nlm.nih.gov/34833382/>
529. Thrombosis and thrombocytopenia syndrome causing isolated symptomatic carotid occlusion after COVID-19 Ad26.COV2.S vaccine (Janssen): <https://pubmed.ncbi.nlm.nih.gov/34670287/>
530. An unusual presentation of acute deep vein thrombosis after Modern COVID-19 vaccine: case report: <https://pubmed.ncbi.nlm.nih.gov/34790811/>
531. Immediate high-dose intravenous immunoglobulins followed by direct thrombin-inhibitor treatment is crucial for survival in Sars-Covid-19-adenoviral vector vaccine-induced immune thrombotic thrombocytopenia VITT with cerebral sinus venous and portal vein thrombosis: <https://pubmed.ncbi.nlm.nih.gov/34023956/>.
532. Thrombosis formation after COVID-19 vaccination immunologic aspects: review article: <https://pubmed.ncbi.nlm.nih.gov/34629931/>
533. Imaging and hematologic findings in thrombosis and thrombocytopenia after vaccination with ChAdOx1 nCoV-19 (AstraZeneca): <https://pubmed.ncbi.nlm.nih.gov/34402666/>
534. Spectrum of neuroimaging findings in post-CoVID-19 vaccination: a case series and review of the literature: <https://pubmed.ncbi.nlm.nih.gov/34842783/>
535. Cerebral venous sinus thrombosis, pulmonary embolism, and thrombocytopenia after COVID-19 vaccination in a Taiwanese man: a case report and review of the literature: <https://pubmed.ncbi.nlm.nih.gov/34630307/>
536. Fatal cerebral venous sinus thrombosis after COVID-19 vaccination: <https://pubmed.ncbi.nlm.nih.gov/33983464/>
537. Autoimmune roots of thrombotic events after COVID-19 vaccination: <https://pubmed.ncbi.nlm.nih.gov/34508917/>.
538. New portal vein thrombosis in cirrhosis: is thrombophilia exacerbated by vaccine or COVID-19: [https://www.jcehepatology.com/article/S0973-6883\(21\)00545-4/fulltext](https://www.jcehepatology.com/article/S0973-6883(21)00545-4/fulltext).
539. Images of immune thrombotic thrombocytopenia induced by Oxford / AstraZeneca® COVID-19 vaccine: <https://pubmed.ncbi.nlm.nih.gov/33962903/>.
540. Cerebral venous sinus thrombosis after vaccination with COVID-19 mRNA of BNT162b2: <https://pubmed.ncbi.nlm.nih.gov/34796065/>.
541. Increased risk of urticaria/angioedema after BNT162b2 mRNA COVID-19 vaccination in health care workers taking ACE inhibitors: <https://pubmed.ncbi.nlm.nih.gov/34579248/>
542. A case of unusual mild clinical presentation of COVID-19 vaccine-induced immune thrombotic thrombocytopenia with splanchnic vein thrombosis: <https://pubmed.ncbi.nlm.nih.gov/34843991/>

543. Cerebral venous sinus thrombosis following vaccination with Pfizer-BioNTech COVID-19 (BNT162b2): <https://pubmed.ncbi.nlm.nih.gov/34595867/>
544. A case of idiopathic thrombocytopenic purpura after a booster dose of COVID-19 BNT162b2 vaccine (Pfizer-Biontech): <https://pubmed.ncbi.nlm.nih.gov/34820240/>
545. Vaccine-induced immune thrombotic immune thrombocytopenia (VITT): targeting pathologic mechanisms with Bruton's tyrosine kinase inhibitors: <https://pubmed.ncbi.nlm.nih.gov/33851389/>
546. Thrombotic thrombocytopenic purpura after vaccination with Ad26.COV2-S: <https://pubmed.ncbi.nlm.nih.gov/33980419/>
547. Thromboembolic events in younger females exposed to Pfizer-BioNTech or Moderna COVID-19 vaccines: <https://pubmed.ncbi.nlm.nih.gov/34264151/>
548. Potential risk of thrombotic events after COVID-19 vaccination with Oxford-AstraZeneca in women receiving estrogen: <https://pubmed.ncbi.nlm.nih.gov/34734086/>
549. Thrombosis after adenovirus-vectored COVID-19 vaccination: a concern for underlying disease: <https://pubmed.ncbi.nlm.nih.gov/34755555/>
550. Adenovirus interactions with platelets and coagulation and vaccine-induced immune thrombotic thrombocytopenia syndrome: <https://pubmed.ncbi.nlm.nih.gov/34407607/>
551. Thrombotic thrombocytopenic purpura: a new threat after COVID bnt162b2 vaccine: <https://pubmed.ncbi.nlm.nih.gov/34264514/>.
552. Unusual site of deep vein thrombosis after vaccination against coronavirus mRNA-2019 coronavirus disease (COVID-19): <https://pubmed.ncbi.nlm.nih.gov/34840204/>
553. Neurological side effects of SARS-CoV-2 vaccines: <https://pubmed.ncbi.nlm.nih.gov/34750810/>
554. Coagulopathies after SARS-CoV-2 vaccination may derive from a combined effect of SARS-CoV-2 spike protein and adenovirus vector-activated signaling pathways: <https://pubmed.ncbi.nlm.nih.gov/34639132/>
555. Isolated pulmonary embolism after COVID vaccination: 2 case reports and a review of acute pulmonary embolism complications and follow-up: <https://pubmed.ncbi.nlm.nih.gov/34804412/>
556. Central retinal vein occlusion after vaccination with SARS-CoV-2 mRNA: case report: <https://pubmed.ncbi.nlm.nih.gov/34571653/>.
557. Complicated case report of long-term vaccine-induced thrombotic immune thrombocytopenia A: <https://pubmed.ncbi.nlm.nih.gov/34835275/>.
558. Deep venous thrombosis after vaccination with Ad26.COV2.S in adult males: <https://pubmed.ncbi.nlm.nih.gov/34659839/>.
559. Neurological autoimmune diseases after SARS-CoV-2 vaccination: a case series: <https://pubmed.ncbi.nlm.nih.gov/34668274/>.
560. Severe autoimmune hemolytic autoimmune anemia after receiving SARS-CoV-2 mRNA vaccine: <https://pubmed.ncbi.nlm.nih.gov/34549821/>
561. Occurrence of COVID-19 variants among recipients of ChAdOx1 nCoV-19 vaccine (recombinant): <https://pubmed.ncbi.nlm.nih.gov/34528522/>
562. Prevalence of thrombocytopenia, anti-platelet factor 4 antibodies, and elevated D-dimer in Thais after vaccination with ChAdOx1 nCoV-19: <https://pubmed.ncbi.nlm.nih.gov/34568726/>
563. Epidemiology of acute myocarditis/pericarditis in Hong Kong adolescents after co-vaccination: <https://academic.oup.com/cid/advance-article-abstract/doi/10.1093/cid/ciab989/644> 5179.

564. Myocarditis after 2019 coronavirus disease mRNA vaccine: a case series and determination of incidence rate: <https://academic.oup.com/cid/advance-article/doi/10.1093/cid/ciab926/6420408>
565. Myocarditis and pericarditis after COVID-19 vaccination: inequalities in age and vaccine types: <https://www.mdpi.com/2075-4426/11/11/1106>
566. Epidemiology and clinical features of myocarditis/pericarditis before the introduction of COVID-19 mRNA vaccine in Korean children: a multicenter study: <https://pubmed.ncbi.nlm.nih.gov/34402230/>
567. Shedding light on post-vaccination myocarditis and pericarditis in COVID-19 and non-COVID-19 vaccine recipients: <https://pubmed.ncbi.nlm.nih.gov/34696294/>
568. Myocarditis Following mRNA COVID-19 Vaccine: https://journals.lww.com/pec-online/Abstract/2021/11000/Myocarditis_Following_mRNA_COVID_19_Vaccine.9.aspx.
569. Myocarditis following BNT162b2 mRNA Covid-19 mRNA vaccine in Israel: <https://pubmed.ncbi.nlm.nih.gov/34614328/>.
570. Myocarditis, pericarditis, and cardiomyopathy following COVID-19 vaccination: [https://www.heartlungcirc.org/article/S1443-9506\(21\)01156-2/fulltext](https://www.heartlungcirc.org/article/S1443-9506(21)01156-2/fulltext)
571. Myocarditis and other cardiovascular complications of COVID-19 mRNA-based COVID-19 vaccines: <https://pubmed.ncbi.nlm.nih.gov/34277198/>
572. Possible Association Between COVID-19 Vaccine and Myocarditis: Clinical and CMR Findings: <https://pubmed.ncbi.nlm.nih.gov/34246586/>
573. Hypersensitivity Myocarditis and COVID-19 Vaccines: <https://pubmed.ncbi.nlm.nih.gov/34856634/>.
574. Severe myocarditis associated with COVID-19 vaccine: zebra or unicorn?: [https://www.internationaljournalofcardiology.com/article/S0167-5273\(21\)01477-7/fulltext](https://www.internationaljournalofcardiology.com/article/S0167-5273(21)01477-7/fulltext).
575. Acute myocardial infarction and myocarditis after COVID-19 vaccination: https://www.ncbi.nlm.nih.gov/labs/pmc/articles/PMC8522388/#ffn_sectitle.
576. Myocarditis after Covid-19 vaccination in a large healthcare organization: https://www.nejm.org/doi/10.1056/NEJMoa2110737?url_ver=Z39.88-2003&rfr_id=ori:rid:crossref.org&rfr_dat=cr_pub%20%20pubmed
577. Association of myocarditis with COVID-19 messenger RNA BNT162b2 vaccine in a case series of children: <https://jamanetwork.com/journals/jamacardiology/fullarticle/2783052>
578. Clinical suspicion of myocarditis temporally related to COVID-19 vaccination in adolescents and young adults: https://www.ahajournals.org/doi/abs/10.1161/CIRCULATIONAHA.121.056583?url_ver=Z39.88-2003&rfr_id=ori:rid:crossref.org&rfr_dat=cr_pub%20%20pubmed
579. STEMI mimicry: focal myocarditis in an adolescent patient after COVID-19 mRNA vaccination.: <https://pubmed.ncbi.nlm.nih.gov/34756746/>
580. Myocarditis and pericarditis in association with COVID-19 mRNA vaccination: cases from a regional pharmacovigilance center: https://www.ncbi.nlm.nih.gov/labs/pmc/articles/PMC8587334/#ffn_sectitle.
581. Myocarditis after COVID-19 mRNA vaccines: <https://pubmed.ncbi.nlm.nih.gov/34546329/>.
582. Patients with acute myocarditis after COVID-19 mRNA vaccination.: <https://jamanetwork.com/journals/jamacardiology/fullarticle/2781602>.
583. Myocarditis after COVID-19 vaccination: a case series: <https://www.sciencedirect.com/science/article/pii/S0264410X21011725?via%3Dihub>.

584. Myocarditis associated with COVID-19 vaccination in adolescents:
<https://publications.aap.org/pediatrics/article/148/5/e2021053427/181357/COVID-19-Vaccination-Associated-Myocarditis-in>.
585. Myocarditis findings on cardiac magnetic resonance imaging after vaccination with COVID-19 mRNA in adolescents: <https://pubmed.ncbi.nlm.nih.gov/34704459/>
586. myocarditis after COVID-19 vaccination: magnetic resonance imaging study:
<https://academic.oup.com/ehjcmimaging/advance-article/doi/10.1093/ehjci/jeab230/6421640>.
587. Acute myocarditis after administration of the second dose of BNT162b2 COVID-19 vaccine:
https://www.ncbi.nlm.nih.gov/labs/pmc/articles/PMC8599115/#ffn_sectitle.
588. Myocarditis after COVID-19 vaccination:
<https://www.sciencedirect.com/science/article/pii/S2352906721001603?via%3Dihub>.
589. Case report: probable myocarditis after Covid-19 mRNA vaccine in a patient with arrhythmogenic left ventricular cardiomyopathy:
<https://pubmed.ncbi.nlm.nih.gov/34712717/>.
590. Acute myocarditis after administration of BNT162b2 vaccine against COVID-19:
<https://www.revespcardiol.org/en-linkresolver-acute-myocarditis-after-administratio-n-bnt162b2-S188558572100133X>.
591. Myocarditis associated with COVID-19 mRNA vaccination:.
https://pubs.rsna.org/doi/10.1148/radiol.2021211430?url_ver=Z39.88-2003&rfr_id=ori:rid:crossref.org&rfr_dat=cr_pub%20%200pubmed.
592. Acute myocarditis after COVID-19 vaccination: a case report:
<https://www.sciencedirect.com/science/article/pii/S0248866321007098?via%3Dihub> b.
593. Acute myopericarditis after COVID-19 vaccination in adolescents:.
<https://pubmed.ncbi.nlm.nih.gov/34589238/>.
594. Perimyocarditis in adolescents after Pfizer-BioNTech COVID-19 vaccination:
<https://academic.oup.com/jpids/article/10/10/962/6329543>.
595. Acute myocarditis associated with anti-COVID-19 vaccination:
<https://ecevr.org/DOIx.php?id=10.7774/cevr.2021.10.2.196>.
596. Myocarditis associated with COVID-19 vaccination: echocardiographic, cardiac CT, and MRI findings: <https://pubmed.ncbi.nlm.nih.gov/34428917/>.
597. Acute symptomatic myocarditis in 7 adolescents after Pfizer-BioNTech COVID-19 vaccination: <https://pubmed.ncbi.nlm.nih.gov/34088762/>.
598. Myocarditis and pericarditis in adolescents after first and second doses of COVID-19 mRNA vaccines: <https://academic.oup.com/ehjqcco/advance-article/doi/10.1093/ehjqcco/qcab090/6442104>.
599. COVID 19 vaccine for adolescents. Concern for myocarditis and pericarditis:
<https://www.mdpi.com/2036-7503/13/3/61>.
600. Cardiac imaging of acute myocarditis after vaccination with COVID-19 mRNA:
<https://pubmed.ncbi.nlm.nih.gov/34402228/> 600.
601. Myocarditis temporally associated with COVID-19 vaccination:
<https://pubmed.ncbi.nlm.nih.gov/34133885/>
602. Acute myocardial injury after COVID-19 vaccination: a case report and review of current evidence from the vaccine adverse event reporting system database:
<https://pubmed.ncbi.nlm.nih.gov/34219532/>
603. Acute myocarditis associated with COVID-19 vaccination: report of a case:
https://www.ncbi.nlm.nih.gov/labs/pmc/articles/PMC8639400/#ffn_sectitle
604. Myocarditis following vaccination with COVID-19 messenger RNA: a Japanese case series: <https://pubmed.ncbi.nlm.nih.gov/34840235/>.

605. Myocarditis in the setting of a recent COVID-19 vaccination: <https://pubmed.ncbi.nlm.nih.gov/34712497/>.
606. Acute myocarditis after a second dose of COVID-19 mRNA vaccine: report of two cases: [https://www.clinicalimaging.org/article/S0899-7071\(21\)00265-5/fulltext](https://www.clinicalimaging.org/article/S0899-7071(21)00265-5/fulltext).
607. Prevalence of thrombocytopenia, antiplatelet factor 4 antibodies, and elevated D-dimer in Thais after vaccination with ChAdOx1 nCoV-19: <https://pubmed.ncbi.nlm.nih.gov/34568726/>
608. Epidemiology of acute myocarditis/pericarditis in Hong Kong adolescents after co-vaccination: <https://academic.oup.com/cid/advance-article-abstract/doi/10.1093/cid/ciab989/6445179>
609. Myocarditis after 2019 coronavirus disease mRNA vaccine: a case series and incidence rate determination: <https://academic.oup.com/cid/advance-article/doi/10.1093/cid/ciab926/6420408>.
610. Myocarditis and pericarditis after COVID-19 vaccination: inequalities in age and vaccine types: <https://www.mdpi.com/2075-4426/11/11/1106>
611. Epidemiology and clinical features of myocarditis/pericarditis before the introduction of COVID-19 mRNA vaccine in Korean children: a multicenter study: <https://pubmed.ncbi.nlm.nih.gov/34402230/>
612. Shedding light on post-vaccination myocarditis and pericarditis in COVID-19 and non-COVID-19 vaccine recipients: <https://pubmed.ncbi.nlm.nih.gov/34696294/>
613. Diffuse prothrombotic syndrome after administration of ChAdOx1 nCoV-19 vaccine: case report: <https://pubmed.ncbi.nlm.nih.gov/34615534/>
614. Three cases of acute venous thromboembolism in women after coronavirus 2019 vaccination: <https://pubmed.ncbi.nlm.nih.gov/34352418/>
615. Clinical and biological features of cerebral venous sinus thrombosis after vaccination with ChAdOx1 nCov-19; <https://jnnp.bmj.com/content/early/2021/09/29/jnnp-2021-327340.long>
616. CAd26.COV2-S vaccination may reveal hereditary thrombophilia: massive cerebral venous sinus thrombosis in a young man with normal platelet count: <https://pubmed.ncbi.nlm.nih.gov/34632750/>
617. Post-mortem findings in vaccine-induced thrombotic thrombocytopenia: <https://haematologica.org/article/view/haematol.2021.279075>
618. COVID-19 vaccine-induced thrombosis: <https://pubmed.ncbi.nlm.nih.gov/34802488/>.
619. Inflammation and platelet activation after COVID-19 vaccines: possible mechanisms behind vaccine-induced immune thrombocytopenia and thrombosis: <https://pubmed.ncbi.nlm.nih.gov/34887867/>.
620. Anaphylactoid reaction and coronary thrombosis related to COVID-19 mRNA vaccine: <https://pubmed.ncbi.nlm.nih.gov/34863404/>.
621. Oxford-AstraZeneca COVID-19 vaccine-induced cerebral venous thrombosis and thrombocytopenia: A missed opportunity for a rapid return of experience: <https://www.sciencedirect.com/science/article/pii/S235255682100093X?via%3Dihub>
622. Occurrence of splenic infarction due to arterial thrombosis after vaccination with COVID-19: <https://pubmed.ncbi.nlm.nih.gov/34876440/>
623. Deep venous thrombosis more than two weeks after COVID-19 vaccination: <https://pubmed.ncbi.nlm.nih.gov/33928773/>
624. Case report: Take a second look: Cerebral venous thrombosis related to Covid-19 vaccination and thrombotic thrombocytopenia syndrome: <https://pubmed.ncbi.nlm.nih.gov/34880826/>
625. Information on ChAdOx1 nCoV-19 vaccine-induced immune-mediated thrombotic thrombocytopenia: <https://pubmed.ncbi.nlm.nih.gov/34587242/>

626. Change in blood viscosity after COVID-19 vaccination: estimation for persons with underlying metabolic syndrome: <https://pubmed.ncbi.nlm.nih.gov/34868465/>
627. Management of a patient with a rare congenital limb malformation syndrome after SARS-CoV-2 vaccine-induced thrombosis and thrombocytopenia (VITT): <https://pubmed.ncbi.nlm.nih.gov/34097311/>
628. Bilateral thalamic stroke: a case of COVID-19 (VITT) vaccine-induced immune thrombotic thrombocytopenia or a coincidence due to underlying risk factors: <https://pubmed.ncbi.nlm.nih.gov/34820232/>.
629. Thrombocytopenia and splanchnic thrombosis after vaccination with Ad26.COV2.S successfully treated with transjugular intrahepatic portosystemic shunt and thrombectomy: <https://onlinelibrary.wiley.com/doi/10.1002/ajh.26258>
630. Incidence of acute ischemic stroke after coronavirus vaccination in Indonesia: case series: <https://pubmed.ncbi.nlm.nih.gov/34579636/>
631. Successful treatment of vaccine-induced immune thrombotic thrombocytopenia in a 26-year-old female patient: <https://pubmed.ncbi.nlm.nih.gov/34614491/>
632. Case report: vaccine-induced immune thrombotic thrombocytopenia in a patient with pancreatic cancer after vaccination with messenger RNA-1273: <https://pubmed.ncbi.nlm.nih.gov/34790684/>
633. Idiopathic external jugular vein thrombophlebitis after coronavirus disease vaccination (COVID-19): <https://pubmed.ncbi.nlm.nih.gov/33624509/>.
634. Squamous cell carcinoma of the lung with hemoptysis following vaccination with tozinameran (BNT162b2, Pfizer-BioNTech): <https://pubmed.ncbi.nlm.nih.gov/34612003/>
635. Vaccine-induced thrombotic thrombocytopenia after Ad26.COV2.S vaccination in a man presenting as acute venous thromboembolism: <https://pubmed.ncbi.nlm.nih.gov/34096082/>
636. Myocarditis associated with COVID-19 vaccination in three adolescent boys: <https://pubmed.ncbi.nlm.nih.gov/34851078/>.
637. Cardiovascular magnetic resonance findings in young adult patients with acute myocarditis after COVID-19 mRNA vaccination: a case series: <https://pubmed.ncbi.nlm.nih.gov/34496880/>
638. Perimyocarditis after vaccination with COVID-19: <https://pubmed.ncbi.nlm.nih.gov/34866957/>
639. Epidemiology of acute myocarditis/pericarditis in Hong Kong adolescents after co-vaccination: <https://pubmed.ncbi.nlm.nih.gov/34849657/>.
640. Myocarditis-induced sudden death after BNT162b2 COVID-19 mRNA vaccination in Korea: case report focusing on histopathological findings: <https://pubmed.ncbi.nlm.nih.gov/34664804/>
641. Acute myocarditis after vaccination with COVID-19 mRNA in adults aged 18 years or older: <https://pubmed.ncbi.nlm.nih.gov/34605853/>
642. Recurrence of acute myocarditis temporally associated with receipt of the 2019 coronavirus mRNA disease vaccine (COVID-19) in an adolescent male: <https://pubmed.ncbi.nlm.nih.gov/34166671/>
643. Young male with myocarditis after mRNA-1273 coronavirus disease-2019 (COVID-19) mRNA vaccination: <https://pubmed.ncbi.nlm.nih.gov/34744118/>
644. Acute myocarditis after SARS-CoV-2 vaccination in a 24-year-old male: <https://pubmed.ncbi.nlm.nih.gov/34334935/>.
645. 68 Ga-DOTATOC digital PET images of inflammatory cell infiltrates in myocarditis after vaccination with COVID-19: <https://pubmed.ncbi.nlm.nih.gov/34746968/>

646. Occurrence of acute infarct-like myocarditis after vaccination with COVID-19: just an accidental coincidence or rather a vaccination-associated autoimmune myocarditis?": <https://pubmed.ncbi.nlm.nih.gov/34333695/>.
647. Self-limited myocarditis presenting with chest pain and ST-segment elevation in adolescents after vaccination with BNT162b2 mRNA vaccine: <https://pubmed.ncbi.nlm.nih.gov/34180390/>
648. Myocarditis Following Immunization with COVID-19 mRNA Vaccines in Members of the U.S. Military: <https://pubmed.ncbi.nlm.nih.gov/34185045/>
649. Myocarditis after BNT162b2 vaccination in a healthy male: <https://pubmed.ncbi.nlm.nih.gov/34229940/>
650. Myopericarditis in a previously healthy adolescent male after COVID-19 vaccination: Case report: <https://pubmed.ncbi.nlm.nih.gov/34133825/>
651. Acute myocarditis after SARS-CoV-2 mRNA-1273 mRNA vaccination: <https://pubmed.ncbi.nlm.nih.gov/34308326/>.
652. Chest pain with abnormal electrocardiogram redevelopment after injection of COVID-19 vaccine manufactured by Moderna: <https://pubmed.ncbi.nlm.nih.gov/34866106/>
653. Biopsy-proven lymphocytic myocarditis after first vaccination with COVID-19 mRNA in a 40-year-old man: case report: <https://pubmed.ncbi.nlm.nih.gov/34487236/>
654. Multimodality imaging and histopathology in a young man presenting with fulminant lymphocytic myocarditis and cardiogenic shock after vaccination with mRNA-1273: <https://pubmed.ncbi.nlm.nih.gov/34848416/>
655. Report of a case of myopericarditis after vaccination with BNT162b2 COVID-19 mRNA in a young Korean male: <https://pubmed.ncbi.nlm.nih.gov/34636504/>
656. Acute myocarditis after Comirnaty vaccination in a healthy male with previous SARS-CoV-2 infection: <https://pubmed.ncbi.nlm.nih.gov/34367386/>
657. Acute myocarditis in a young adult two days after vaccination with Pfizer: <https://pubmed.ncbi.nlm.nih.gov/34709227/>
658. Case report: acute fulminant myocarditis and cardiogenic shock after messenger RNA coronavirus vaccination in 2019 requiring extracorporeal cardiopulmonary resuscitation: <https://pubmed.ncbi.nlm.nih.gov/34778411/>
659. Acute myocarditis after 2019 coronavirus disease vaccination: <https://pubmed.ncbi.nlm.nih.gov/34734821/>
660. A series of patients with myocarditis after vaccination against SARS-CoV-2 with mRNA-1279 and BNT162b2: <https://pubmed.ncbi.nlm.nih.gov/34246585/>
661. Myopericarditis after Pfizer messenger ribonucleic acid coronavirus coronavirus disease vaccine in adolescents: <https://pubmed.ncbi.nlm.nih.gov/34228985/>
662. Post-vaccination multisystem inflammatory syndrome in adults without evidence of prior SARS-CoV-2 infection: <https://pubmed.ncbi.nlm.nih.gov/34852213/>
663. Acute myocarditis defined after vaccination with 2019 mRNA of coronavirus disease: <https://pubmed.ncbi.nlm.nih.gov/34866122/>
664. Biventricular systolic dysfunction in acute myocarditis after SARS-CoV-2 mRNA-1273 vaccination: <https://pubmed.ncbi.nlm.nih.gov/34601566/>
665. Myocarditis following COVID-19 vaccination: MRI study: <https://pubmed.ncbi.nlm.nih.gov/34739045/>.
666. Acute myocarditis after COVID-19 vaccination: case report: https://docs.google.com/document/d/1Hc4bh_qNbZ7UVm5BLxkRdMPnnI9zcCsl/e/dit#.
667. Association of myocarditis with COVID-19 messenger RNA BNT162b2 vaccine COVID-19 in a case series of children: <https://pubmed.ncbi.nlm.nih.gov/34374740/>

668. Clinical suspicion of myocarditis temporally related to COVID-19 vaccination in adolescents and young adults: <https://pubmed.ncbi.nlm.nih.gov/34865500/>
669. Myocarditis following vaccination with Covid-19 in a large healthcare organization: <https://pubmed.ncbi.nlm.nih.gov/34614329/>
670. AstraZeneca COVID-19 vaccine and Guillain-Barré syndrome in Tasmania: a causal link: <https://pubmed.ncbi.nlm.nih.gov/34560365/>
671. COVID-19, Guillain-Barré and vaccineA dangerous mix: <https://pubmed.ncbi.nlm.nih.gov/34108736/>.
672. Guillain-Barré syndrome after the first dose of Pfizer-BioNTech COVID-19 vaccine: case report and review of reported cases: <https://pubmed.ncbi.nlm.nih.gov/34796417/>.
673. Guillain-Barre syndrome after BNT162b2 COVID-19 vaccine: <https://link.springer.com/article/10.1007%2Fs10072-021-05523-5>.
674. COVID-19 adenovirus vaccines and Guillain-Barré syndrome with facial palsy: <https://onlinelibrary.wiley.com/doi/10.1002/ana.26258>.
675. Association of receipt association of Ad26.COV2.S COVID-19 vaccine with presumed Guillain-Barre syndrome, February-July 2021: <https://jamanetwork.com/journals/jama/fullarticle/2785009>
676. A case of Guillain-Barré syndrome after Pfizer COVID-19 vaccine: <https://pubmed.ncbi.nlm.nih.gov/34567447/>
677. Guillain-Barré syndrome associated with COVID-19 vaccination: <https://pubmed.ncbi.nlm.nih.gov/34648420/>.
678. Rate of recurrent Guillain-Barré syndrome after COVID-19 BNT162b2 mRNA vaccine: <https://jamanetwork.com/journals/jamaneurology/fullarticle/2783708>
679. Guillain-Barre syndrome after COVID-19 vaccination in an adolescent: [https://www.pedneur.com/article/S0887-8994\(21\)00221-6/fulltext](https://www.pedneur.com/article/S0887-8994(21)00221-6/fulltext).
680. Guillain-Barre syndrome after ChAdOx1-S / nCoV-19 vaccination: <https://pubmed.ncbi.nlm.nih.gov/34114256/>.
681. Guillain-Barre syndrome after COVID-19 mRNA-1273 vaccine: case report: <https://pubmed.ncbi.nlm.nih.gov/34767184/>.
682. Guillain-Barre syndrome following SARS-CoV-2 vaccination in 19 patients: <https://pubmed.ncbi.nlm.nih.gov/34644738/>.
683. Guillain-Barre syndrome presenting with facial diplegia following vaccination with COVID-19 in two patients: <https://pubmed.ncbi.nlm.nih.gov/34649856/>
684. A rare case of Guillain-Barré syndrome after COVID-19 vaccination: <https://pubmed.ncbi.nlm.nih.gov/34671572/>
685. Neurological complications of COVID-19: Guillain-Barre syndrome after Pfizer COVID-19 vaccine: <https://pubmed.ncbi.nlm.nih.gov/33758714/>
686. COVID-19 vaccine causing Guillain-Barre syndrome, an uncommon potential side effect: <https://pubmed.ncbi.nlm.nih.gov/34484780/>
687. Guillain-Barre syndrome after the first dose of COVID-19 vaccination: case report; <https://pubmed.ncbi.nlm.nih.gov/34779385/>.
688. Miller Fisher syndrome after Pfizer COVID-19 vaccine: <https://pubmed.ncbi.nlm.nih.gov/34817727/>.
689. Miller Fisher syndrome after 2019 BNT162b2 mRNA coronavirus vaccination: <https://pubmed.ncbi.nlm.nih.gov/34789193/>.
690. Bilateral facial weakness with a variant of paresthesia of Guillain-Barre syndrome after Vaxzevria COVID-19 vaccine: <https://pubmed.ncbi.nlm.nih.gov/34261746/>
691. Guillain-Barre syndrome after the first injection of ChAdOx1 nCoV-19 vaccine: first report: <https://pubmed.ncbi.nlm.nih.gov/34217513/>.

692. A case of sensory ataxic Guillain-Barre syndrome with immunoglobulin G anti-GM1 antibodies after first dose of COVID-19 BNT162b2 mRNA vaccine (Pfizer): <https://pubmed.ncbi.nlm.nih.gov/34871447/>
693. Reporting of acute inflammatory neuropathies with COVID-19 vaccines: subgroup disproportionality analysis in VigiBase: <https://pubmed.ncbi.nlm.nih.gov/34579259/>
694. A variant of Guillain-Barré syndrome after SARS-CoV-2 vaccination: AMSAN: <https://pubmed.ncbi.nlm.nih.gov/34370408/>.
695. A rare variant of Guillain-Barré syndrome after vaccination with Ad26.COV2.S: <https://pubmed.ncbi.nlm.nih.gov/34703690/>.
696. Guillain-Barré syndrome after SARS-CoV-2 vaccination in a patient with previous vaccine-associated Guillain-Barré syndrome: <https://pubmed.ncbi.nlm.nih.gov/34810163/>
698. Guillain-Barré syndrome in an Australian state using mRNA and adenovirus-vector SARS-CoV-2 vaccines: <https://onlinelibrary.wiley.com/doi/10.1002/ana.26218>.
699. Acute transverse myelitis after SARS-CoV-2 vaccination: case report and review of the literature: <https://pubmed.ncbi.nlm.nih.gov/34482455/>.
700. Variant Guillain-Barré syndrome occurring after SARS-CoV-2 vaccination: <https://pubmed.ncbi.nlm.nih.gov/34114269/>.
701. Guillain-Barre syndrome with axonal variant temporally associated with Modern SARS-CoV-2 mRNA-based vaccine: <https://pubmed.ncbi.nlm.nih.gov/34722067/>
702. Guillain-Barre syndrome after the first dose of SARS-CoV-2 vaccine: a temporary occurrence, not a causal association: <https://pubmed.ncbi.nlm.nih.gov/33968610/>
703. SARS-CoV-2 vaccines can be complicated not only by Guillain-Barré syndrome but also by distal small fiber neuropathy: <https://pubmed.ncbi.nlm.nih.gov/34525410/>
704. Clinical variant of Guillain-Barré syndrome with prominent facial diplegia after AstraZeneca 2019 coronavirus disease vaccine: <https://pubmed.ncbi.nlm.nih.gov/34808658/>
705. Adverse event reporting and risk of Bell's palsy after COVID-19 vaccination: [https://www.thelancet.com/journals/laninf/article/PIIS1473-3099\(21\)00646-0/fulltext](https://www.thelancet.com/journals/laninf/article/PIIS1473-3099(21)00646-0/fulltext).
706. Bilateral facial nerve palsy and COVID-19 vaccination: causality or coincidence?: <https://pubmed.ncbi.nlm.nih.gov/34522557/>
707. Left Bell's palsy after the first dose of mRNA-1273 SARS-CoV-2 vaccine: case report: <https://pubmed.ncbi.nlm.nih.gov/34763263/>.
708. Bell's palsy after inactivated vaccination with COVID-19 in a patient with a history of recurrent Bell's palsy: case report: <https://pubmed.ncbi.nlm.nih.gov/34621891/>
709. Neurological complications after the first dose of COVID-19 vaccines and SARS-CoV-2 infection: <https://pubmed.ncbi.nlm.nih.gov/34697502/>
710. Type I interferons as a potential mechanism linking COVID-19 mRNA vaccines with Bell's palsy: <https://pubmed.ncbi.nlm.nih.gov/33858693/>
711. Acute transverse myelitis following inactivated COVID-19 vaccine: <https://pubmed.ncbi.nlm.nih.gov/34370410/>
712. Acute transverse myelitis after COVID-19 vaccination: <https://pubmed.ncbi.nlm.nih.gov/34579245/>.
713. A case of longitudinally extensive transverse myelitis following Covid-19 vaccination: <https://pubmed.ncbi.nlm.nih.gov/34182207/>
714. Post COVID-19 transverse myelitis; a case report with review of the literature: <https://pubmed.ncbi.nlm.nih.gov/34457267/>.
715. Beware of neuromyelitis optica spectrum disorder after vaccination with inactivated virus for COVID-19: <https://pubmed.ncbi.nlm.nih.gov/34189662/>

716. Neuromyelitis optica in a healthy woman after vaccination against severe acute respiratory syndrome coronavirus 2 mRNA-1273: <https://pubmed.ncbi.nlm.nih.gov/34660149/>
717. Acute bilateral bilateral optic neuritis/chiasm with longitudinal extensive transverse myelitis in long-standing stable multiple sclerosis after vector-based vaccination against SARS-CoV-2: <https://pubmed.ncbi.nlm.nih.gov/34131771/>
718. A case series of acute pericarditis after vaccination with COVID-19 in the context of recent reports from Europe and the United States: <https://pubmed.ncbi.nlm.nih.gov/34635376/>
719. Acute pericarditis and cardiac tamponade after vaccination with Covid-19: <https://pubmed.ncbi.nlm.nih.gov/34749492/>
720. Myocarditis and pericarditis in adolescents after the first and second doses of COVID-19 mRNA vaccines: <https://pubmed.ncbi.nlm.nih.gov/34849667/>
721. Perimyocarditis in adolescents after Pfizer-BioNTech COVID-19 vaccine: <https://pubmed.ncbi.nlm.nih.gov/34319393/>
722. Acute myopericarditis after COVID-19 vaccine in adolescents: <https://pubmed.ncbi.nlm.nih.gov/34589238/>
723. Pericarditis after administration of the BNT162b2 mRNA vaccine COVID-19: <https://pubmed.ncbi.nlm.nih.gov/34149145/>
724. Case report: symptomatic pericarditis post COVID-19 vaccination: <https://pubmed.ncbi.nlm.nih.gov/34693198/>
725. An outbreak of Still's disease after COVID-19 vaccination in a 34-year-old patient: <https://pubmed.ncbi.nlm.nih.gov/34797392/>
726. Lessons of the month 3: Hemophagocytic lymphohistiocytosis following COVID-19 vaccination (ChAdOx1 nCoV-19): <https://pubmed.ncbi.nlm.nih.gov/34862234/>
727. Myocarditis after SARS-CoV-2 mRNA vaccination, a case series: <https://pubmed.ncbi.nlm.nih.gov/34396358/>
728. Miller-Fisher syndrome and Guillain-Barré syndrome overlap syndrome in a patient after Oxford-AstraZeneca SARS-CoV-2 vaccination: <https://pubmed.ncbi.nlm.nih.gov/34848426/>
729. Immune-mediated disease outbreaks or new-onset disease in 27 subjects after mRNA/DNA vaccination against SARS-CoV-2: <https://pubmed.ncbi.nlm.nih.gov/33946748/>
730. Post-mortem investigation of deaths after vaccination with COVID-19 vaccines: <https://pubmed.ncbi.nlm.nih.gov/34591186/>
731. Acute kidney injury with macroscopic hematuria and IgA nephropathy after COVID-19 vaccination: <https://pubmed.ncbi.nlm.nih.gov/34352309/>
732. Relapse of immune thrombocytopenia after covid-19 vaccination in young male patient: <https://pubmed.ncbi.nlm.nih.gov/34804803/>
733. Immune thrombocytopenic purpura associated with COVID-19 mRNA vaccine Pfizer-BioNTech BNT16B2b2: <https://pubmed.ncbi.nlm.nih.gov/34077572/>
734. Retinal hemorrhage after SARS-CoV-2 vaccination: <https://pubmed.ncbi.nlm.nih.gov/34884407/>
735. Case report: anti-neutrophil cytoplasmic antibody-associated vasculitis with acute renal failure and pulmonary hemorrhage can occur after COVID-19 vaccination: <https://pubmed.ncbi.nlm.nih.gov/34859017/>
736. Intracerebral hemorrhage due to vasculitis following COVID-19 vaccination: case report: <https://pubmed.ncbi.nlm.nih.gov/34783899/>
737. Peduncular, symptomatic cavernous bleeding after immune thrombocytopenia-induced SARS-CoV-2 vaccination: <https://pubmed.ncbi.nlm.nih.gov/34549178/>

738. Brain death in a vaccinated patient with COVID-19 infection: <https://pubmed.ncbi.nlm.nih.gov/34656887/>
739. Generalized purpura annularis telangiectodes after SARS-CoV-2 mRNA vaccination: <https://pubmed.ncbi.nlm.nih.gov/34236717/>.
740. Lobar hemorrhage with ventricular rupture shortly after the first dose of a SARS-CoV-2 mRNA-based SARS-CoV-2 vaccine: <https://pubmed.ncbi.nlm.nih.gov/34729467/>.
741. A case of outbreak of macroscopic hematuria and IgA nephropathy after SARS-CoV-2 vaccination: <https://pubmed.ncbi.nlm.nih.gov/33932458/>
742. Acral hemorrhage after administration of the second dose of SARS-CoV-2 vaccine. A post-vaccination reaction: <https://pubmed.ncbi.nlm.nih.gov/34092400/> 742.
743. Severe immune thrombocytopenic purpura after SARS-CoV-2 vaccine: <https://pubmed.ncbi.nlm.nih.gov/34754937/>
744. Gross hematuria after severe acute respiratory syndrome coronavirus 2 vaccination in 2 patients with IgA nephropathy: <https://pubmed.ncbi.nlm.nih.gov/33771584/>
745. Autoimmune encephalitis after ChAdOx1-S SARS-CoV-2 vaccination: <https://pubmed.ncbi.nlm.nih.gov/34846583/>
746. COVID-19 vaccine and death: causality algorithm according to the WHO eligibility diagnosis: <https://pubmed.ncbi.nlm.nih.gov/34073536/>
747. Bell's palsy after vaccination with mRNA (BNT162b2) and inactivated (CoronaVac) SARS-CoV-2 vaccines: a case series and a nested case-control study: <https://pubmed.ncbi.nlm.nih.gov/34411532/>
748. Epidemiology of myocarditis and pericarditis following mRNA vaccines in Ontario, Canada: by vaccine product, schedule, and interval: <https://www.medrxiv.org/content/10.1101/2021.12.02.21267156v1>
749. Anaphylaxis following Covid-19 vaccine in a patient with cholinergic urticaria: <https://pubmed.ncbi.nlm.nih.gov/33851711/>
750. Anaphylaxis induced by CoronaVac COVID-19 vaccine: clinical features and results of revaccination: <https://pubmed.ncbi.nlm.nih.gov/34675550/>.
751. Anaphylaxis after Modern COVID-19 vaccine: <https://pubmed.ncbi.nlm.nih.gov/34734159/>.
752. Association of self-reported history of high-risk allergy with allergy symptoms after COVID-19 vaccination: <https://pubmed.ncbi.nlm.nih.gov/34698847/>
753. Sex differences in the incidence of anaphylaxis to LNP-mRNA vaccines COVID-19: <https://pubmed.ncbi.nlm.nih.gov/34020815/>
754. Allergic reactions, including anaphylaxis, after receiving the first dose of Pfizer-BioNTech COVID-19 vaccine – United States, December 14 to 23, 2020: <https://pubmed.ncbi.nlm.nih.gov/33641264/>
755. Allergic reactions, including anaphylaxis, after receiving the first dose of Modern COVID-19 vaccine – United States, December 21, 2020 to January 10, 2021: <https://pubmed.ncbi.nlm.nih.gov/33641268/>
756. Prolonged anaphylaxis to Pfizer 2019 coronavirus disease vaccine: a case report and mechanism of action: <https://pubmed.ncbi.nlm.nih.gov/33834172/>
757. Pseudo-anaphylaxis reactions to Pfizer BNT162b2 vaccine: report of 3 cases of anaphylaxis following vaccination with Pfizer BNT162b2: <https://pubmed.ncbi.nlm.nih.gov/34579211/>
758. Biphasic anaphylaxis after first dose of 2019 messenger RNA coronavirus disease vaccine with positive polysorbate 80 skin test result: <https://pubmed.ncbi.nlm.nih.gov/34343674/>
759. Acute myocardial infarction and myocarditis after COVID-19 vaccination: <https://pubmed.ncbi.nlm.nih.gov/34586408/>

760. Takotsubo syndrome after COVID-19 vaccination:
<https://pubmed.ncbi.nlm.nih.gov/34539938/>.
761. Takotsubo cardiomyopathy after coronavirus 2019 vaccination in patient on maintenance hemodialysis: <https://pubmed.ncbi.nlm.nih.gov/34731486/>.
762. Premature myocardial infarction or side effect of COVID-19 vaccine:
<https://pubmed.ncbi.nlm.nih.gov/33824804/>
763. Myocardial infarction, stroke, and pulmonary embolism after BNT162b2 mRNA COVID-19 vaccine in persons aged 75 years or older:
<https://pubmed.ncbi.nlm.nih.gov/34807248/>
764. Kounis syndrome type 1 induced by inactivated SARS-COV-2 vaccine:
<https://pubmed.ncbi.nlm.nih.gov/34148772/>
765. Acute myocardial infarction within 24 hours after COVID-19 vaccination: is Kounis syndrome the culprit: <https://pubmed.ncbi.nlm.nih.gov/34702550/>
766. Deaths associated with the recently launched SARS-CoV-2 vaccination (Comirnaty®): <https://pubmed.ncbi.nlm.nih.gov/33895650/>
767. Deaths associated with recently launched SARS-CoV-2 vaccination:
<https://pubmed.ncbi.nlm.nih.gov/34425384/>
768. A case of acute encephalopathy and non-ST-segment elevation myocardial infarction after vaccination with mRNA-1273: possible adverse effect:
<https://pubmed.ncbi.nlm.nih.gov/34703815/> 767.
769. COVID-19 vaccine-induced urticarial vasculitis:
<https://pubmed.ncbi.nlm.nih.gov/34369046/>.
770. ANCA-associated vasculitis after Pfizer-BioNTech COVID-19 vaccine:
<https://pubmed.ncbi.nlm.nih.gov/34280507/>.
771. New-onset leukocytoclastic vasculitis after COVID-19 vaccine:
<https://pubmed.ncbi.nlm.nih.gov/34241833/>
772. Cutaneous small vessel vasculitis after COVID-19 vaccine:
<https://pubmed.ncbi.nlm.nih.gov/34529877/>.
773. Outbreak of leukocytoclastic vasculitis after COVID-19 vaccine:
<https://pubmed.ncbi.nlm.nih.gov/33928638/>
774. Leukocytoclastic vasculitis after exposure to COVID-19 vaccine:
<https://pubmed.ncbi.nlm.nih.gov/34836739/>
775. Vasculitis and bursitis in [18 F] FDG-PET/CT after COVID-19 mRNA vaccine: post hoc ergo propter hoc?; <https://pubmed.ncbi.nlm.nih.gov/34495381/>.
776. Cutaneous lymphocytic vasculitis after administration of COVID-19 mRNA vaccine: <https://pubmed.ncbi.nlm.nih.gov/34327795/>
777. Cutaneous leukocytoclastic vasculitis induced by Sinovac COVID-19 vaccine:
<https://pubmed.ncbi.nlm.nih.gov/34660867/>.
778. Case report: ANCA-associated vasculitis presenting with rhabdomyolysis and crescentic Pauci-Immune glomerulonephritis after vaccination with Pfizer-BioNTech COVID-19 mRNA: <https://pubmed.ncbi.nlm.nih.gov/34659268/>
779. Reactivation of IgA vasculitis after vaccination with COVID-19:
<https://pubmed.ncbi.nlm.nih.gov/34848431/>
780. Varicella-zoster virus-related small-vessel vasculitis after Pfizer-BioNTech COVID-19 vaccination: <https://pubmed.ncbi.nlm.nih.gov/34310759/>.
781. Imaging in vascular medicine: leukocytoclastic vasculitis after COVID-19 vaccine booster: <https://pubmed.ncbi.nlm.nih.gov/34720009/>
782. A rare case of Henoch-Schönlein purpura after a case report of COVID-19 vaccine:
<https://pubmed.ncbi.nlm.nih.gov/34518812/>
783. Cutaneous vasculitis following COVID-19 vaccination:
<https://pubmed.ncbi.nlm.nih.gov/34611627/>.

784. Possible case of COVID-19 mRNA vaccine-induced small-vessel vasculitis: <https://pubmed.ncbi.nlm.nih.gov/34705320/>.
785. IgA vasculitis following COVID-19 vaccination in an adult: <https://pubmed.ncbi.nlm.nih.gov/34779011/>
786. Propylthiouracil-induced anti-neutrophil cytoplasmic antibody-associated vasculitis following vaccination with COVID-19: <https://pubmed.ncbi.nlm.nih.gov/34451967/>
787. Coronavirus disease vaccine 2019 (COVID-19) in systemic lupus erythematosus and neutrophil anti-cytoplasmic antibody-associated vasculitis: <https://pubmed.ncbi.nlm.nih.gov/33928459/>
788. Reactivation of IgA vasculitis after COVID-19 vaccination: <https://pubmed.ncbi.nlm.nih.gov/34250509/>
789. Clinical and histopathologic spectrum of delayed adverse skin reactions after COVID-19 vaccination: <https://pubmed.ncbi.nlm.nih.gov/34292611/>.
790. First description of immune complex vasculitis after COVID-19 vaccination with BNT162b2: case report: <https://pubmed.ncbi.nlm.nih.gov/34530771/>.
791. Nephrotic syndrome and vasculitis after SARS-CoV-2 vaccine: true association or circumstantial: <https://pubmed.ncbi.nlm.nih.gov/34245294/>.
792. Occurrence of de novo cutaneous vasculitis after vaccination against coronavirus disease (COVID-19): <https://pubmed.ncbi.nlm.nih.gov/34599716/>.
793. Asymmetric cutaneous vasculitis after COVID-19 vaccination with unusual preponderance of eosinophils: <https://pubmed.ncbi.nlm.nih.gov/34115904/>.
794. Henoch-Schönlein purpura occurring after vaccination with COVID-19: <https://pubmed.ncbi.nlm.nih.gov/34247902/>.
795. Henoch-Schönlein purpura following the first dose of COVID-19 viral vector vaccine: case report: <https://pubmed.ncbi.nlm.nih.gov/34696186/>.
796. Granulomatous vasculitis after AstraZeneca anti-SARS-CoV-2 vaccine: <https://pubmed.ncbi.nlm.nih.gov/34237323/>.
797. Acute retinal necrosis due to varicella zoster virus reactivation after vaccination with BNT162b2 COVID-19 mRNA: <https://pubmed.ncbi.nlm.nih.gov/34851795/>.
798. A case of generalized Sweet's syndrome with vasculitis triggered by recent vaccination with COVID-19: <https://pubmed.ncbi.nlm.nih.gov/34849386/>
799. Small-vessel vasculitis following Oxford-AstraZeneca vaccination against SARS-CoV-2: <https://pubmed.ncbi.nlm.nih.gov/34310763/>
800. Relapse of microscopic polyangiitis after COVID-19 vaccination: case report: <https://pubmed.ncbi.nlm.nih.gov/34251683/>.
801. Cutaneous vasculitis after severe acute respiratory syndrome coronavirus 2 vaccine: <https://pubmed.ncbi.nlm.nih.gov/34557622/>.
802. Recurrent herpes zoster after COVID-19 vaccination in patients with chronic urticaria on cyclosporine treatment – A report of 3 cases: <https://pubmed.ncbi.nlm.nih.gov/34510694/>
803. Leukocytoclastic vasculitis after coronavirus disease vaccination 2019: <https://pubmed.ncbi.nlm.nih.gov/34713472/> 803.
804. Outbreaks of mixed cryoglobulinemia vasculitis after vaccination against SARS-CoV-2: <https://pubmed.ncbi.nlm.nih.gov/34819272/>
805. Cutaneous small-vessel vasculitis after vaccination with a single dose of Janssen Ad26.COV2.S: <https://pubmed.ncbi.nlm.nih.gov/34337124/>
806. Case of immunoglobulin A vasculitis after vaccination against coronavirus disease 2019: <https://pubmed.ncbi.nlm.nih.gov/34535924/>
807. Rapid progression of angioimmunoblastic T-cell lymphoma after BNT162b2 mRNA booster vaccination: case report:

- https://www.frontiersin.org/articles/10.3389/fmed.2021.798095/full?fbclid=IwAR3c kIK1OuR4unrknRvUSuj1LWiTJvvvg-BF4JZZC xv_wQMKZpvIznABN2dE.
808. COVID-19 mRNA vaccination-induced lymphadenopathy mimics lymphoma progression on FDG PET / CT: <https://pubmed.ncbi.nlm.nih.gov/33591026/>
809. Lymphadenopathy in COVID-19 vaccine recipients: diagnostic dilemma in oncology patients: <https://pubmed.ncbi.nlm.nih.gov/33625300/>
810. Hypermetabolic lymphadenopathy after administration of BNT162b2 mRNA vaccine Covid-19: incidence assessed by [18 F] FDG PET-CT and relevance for study interpretation: <https://pubmed.ncbi.nlm.nih.gov/33774684/>
811. Lymphadenopathy after COVID-19 vaccination: review of imaging findings: <https://pubmed.ncbi.nlm.nih.gov/33985872/>
812. Evolution of bilateral hypermetabolic axillary hypermetabolic lymphadenopathy on FDG PET/CT after 2-dose COVID-19 vaccination: <https://pubmed.ncbi.nlm.nih.gov/34735411/>
813. Lymphadenopathy associated with COVID-19 vaccination on FDG PET/CT: distinguishing features in adenovirus-vectored vaccine: <https://pubmed.ncbi.nlm.nih.gov/34115709/>.
814. COVID-19 vaccination-induced lymphadenopathy in a specialized breast imaging clinic in Israel: analysis of 163 cases: <https://pubmed.ncbi.nlm.nih.gov/34257025/>.
815. COVID-19 vaccine-related axillary lymphadenopathy in breast cancer patients: case series with literature review: <https://pubmed.ncbi.nlm.nih.gov/34836672/>.
816. Coronavirus disease vaccine 2019 mimics lymph node metastases in patients undergoing skin cancer follow-up: a single-center study: <https://pubmed.ncbi.nlm.nih.gov/34280870/>
817. COVID-19 post-vaccination lymphadenopathy: report of fine-needle aspiration biopsy cytologic findings: <https://pubmed.ncbi.nlm.nih.gov/34432391/>
818. Regional lymphadenopathy after COVID-19 vaccination: review of the literature and considerations for patient management in breast cancer care: <https://pubmed.ncbi.nlm.nih.gov/34731748/>
819. Subclinical axillary lymphadenopathy associated with COVID-19 vaccination on screening mammography: <https://pubmed.ncbi.nlm.nih.gov/34906409/>
820. Do you want even more proof? Listed here are 140 references to adverse events of COVID injection that may occur in children. Acute-onset supraclavicular lymphadenopathy coincident with intramuscular mRNA vaccination against COVID-19 may be related to the injection technique of the vaccine, Spain, January and February 2021: <https://pubmed.ncbi.nlm.nih.gov/33706861/>
821. Supraclavicular lymphadenopathy after COVID-19 vaccination in Korea: serial follow-up by ultrasonography: <https://pubmed.ncbi.nlm.nih.gov/34116295/>
822. Oxford-AstraZeneca COVID-19 vaccination induced lymphadenopathy on [18F] choline PET / CT, not just an FDG finding: <https://pubmed.ncbi.nlm.nih.gov/33661328/>
823. Biphasic anaphylaxis after exposure to the first dose of Pfizer-BioNTech COVID-19 mRNA vaccine COVID-19: <https://pubmed.ncbi.nlm.nih.gov/34050949/>
824. Axillary adenopathy associated with COVID-19 vaccination: imaging findings and follow-up recommendations in 23 women: <https://pubmed.ncbi.nlm.nih.gov/33624520/>
825. A case of cervical lymphadenopathy following COVID-19 vaccination: <https://pubmed.ncbi.nlm.nih.gov/34141500/>
826. Unique imaging findings of neurologic phantosmia after Pfizer-BioNtech COVID-19 vaccination: a case report: <https://pubmed.ncbi.nlm.nih.gov/34096896/>

827. Thrombotic adverse events reported for Moderna, Pfizer, and Oxford-AstraZeneca COVID-19 vaccines: comparison of occurrence and clinical outcomes in the EudraVigilance database: <https://pubmed.ncbi.nlm.nih.gov/34835256/>
828. Unilateral lymphadenopathy after COVID-19 vaccination: a practical management plan for radiologists of all specialties: <https://pubmed.ncbi.nlm.nih.gov/33713605/>
829. Unilateral axillary adenopathy in the setting of COVID-19 vaccination: follow-up: <https://pubmed.ncbi.nlm.nih.gov/34298342/>
830. A systematic review of cases of CNS demyelination following COVID-19 vaccination: <https://pubmed.ncbi.nlm.nih.gov/34839149/>
831. Supraclavicular lymphadenopathy after COVID-19 vaccination: an increasing presentation in the two-week wait neck lump clinic: <https://pubmed.ncbi.nlm.nih.gov/33685772/>
832. COVID-19 vaccine-related axillary and cervical lymphadenopathy in patients with current or previous breast cancer and other malignancies: cross-sectional imaging findings on MRI, CT and PET-CT: <https://pubmed.ncbi.nlm.nih.gov/34719892/>
833. Adenopathy after COVID-19 vaccination: <https://pubmed.ncbi.nlm.nih.gov/33625299/>.
834. Incidence of axillary adenopathy on breast imaging after vaccination with COVID-19: <https://pubmed.ncbi.nlm.nih.gov/34292295/>.
835. COVID-19 vaccination and lower cervical lymphadenopathy in two-week neck lump clinic: a follow-up audit: <https://pubmed.ncbi.nlm.nih.gov/33947605/>.
836. Cervical lymphadenopathy after coronavirus disease vaccination 2019: clinical features and implications for head and neck cancer services: <https://pubmed.ncbi.nlm.nih.gov/34526175/>
837. Lymphadenopathy associated with the COVID-19 vaccine: <https://pubmed.ncbi.nlm.nih.gov/33786231/>
838. Evolution of lymphadenopathy on PET/MRI after COVID-19 vaccination: <https://pubmed.ncbi.nlm.nih.gov/33625301/>.
839. Autoimmune hepatitis triggered by SARS-CoV-2 vaccination: <https://pubmed.ncbi.nlm.nih.gov/34332438/>.
840. New-onset nephrotic syndrome after Janssen COVID-19 vaccination: case report and literature review: <https://pubmed.ncbi.nlm.nih.gov/34342187/>.
841. Massive cervical lymphadenopathy following vaccination with COVID-19: <https://pubmed.ncbi.nlm.nih.gov/34601889/>
842. ANCA glomerulonephritis following Modern COVID-19 vaccination: <https://pubmed.ncbi.nlm.nih.gov/34081948/>
843. Month 1 lessons: extensive longitudinal transverse myelitis following AstraZeneca COVID-19 vaccination: <https://pubmed.ncbi.nlm.nih.gov/34507942/>.
844. Systemic capillary extravasation syndrome after vaccination with ChAdOx1 nCoV-19 (Oxford-AstraZeneca): <https://pubmed.ncbi.nlm.nih.gov/34362727/>
845. Unilateral axillary lymphadenopathy related to COVID-19 vaccine: pattern on screening breast MRI allowing benign evaluation: <https://pubmed.ncbi.nlm.nih.gov/34325221/>
846. Axillary lymphadenopathy in patients with recent Covid-19 vaccination: a new diagnostic dilemma: <https://pubmed.ncbi.nlm.nih.gov/34825530/>.
847. Minimal change disease and acute kidney injury after Pfizer-BioNTech COVID-19 vaccine: <https://pubmed.ncbi.nlm.nih.gov/34000278/>
848. COVID-19 vaccine-induced unilateral axillary adenopathy: follow-up evaluation in the USA: <https://pubmed.ncbi.nlm.nih.gov/34655312/>.
849. Gastroparesis after Pfizer-BioNTech COVID-19 vaccination: <https://pubmed.ncbi.nlm.nih.gov/34187985/>.

850. Acute-onset supraclavicular lymphadenopathy coincident with intramuscular mRNA vaccination against COVID-19 may be related to the injection technique of the vaccine, Spain, January and February 2021: <https://pubmed.ncbi.nlm.nih.gov/33706861/>
851. Supraclavicular lymphadenopathy after COVID-19 vaccination in Korea: serial follow-up by ultrasonography: <https://pubmed.ncbi.nlm.nih.gov/34116295/>
852. Oxford-AstraZeneca COVID-19 vaccination induced lymphadenopathy on [18F] choline PET / CT, not just an FDG finding: <https://pubmed.ncbi.nlm.nih.gov/33661328/>
853. Biphasic anaphylaxis after exposure to the first dose of Pfizer-BioNTech COVID-19 mRNA vaccine COVID-19: <https://pubmed.ncbi.nlm.nih.gov/34050949/>
854. Axillary adenopathy associated with COVID-19 vaccination: imaging findings and follow-up recommendations in 23 women: <https://pubmed.ncbi.nlm.nih.gov/33624520/>
855. A case of cervical lymphadenopathy following COVID-19 vaccination: <https://pubmed.ncbi.nlm.nih.gov/34141500/>
856. Unique imaging findings of neurologic phantasmia after Pfizer-BioNtech COVID-19 vaccination: a case report: <https://pubmed.ncbi.nlm.nih.gov/34096896/>
857. Thrombotic adverse events reported for Moderna, Pfizer, and Oxford-AstraZeneca COVID-19 vaccines: comparison of occurrence and clinical outcomes in the EudraVigilance database: <https://pubmed.ncbi.nlm.nih.gov/34835256/>
858. Unilateral lymphadenopathy after COVID-19 vaccination: a practical management plan for radiologists of all specialties: <https://pubmed.ncbi.nlm.nih.gov/33713605/>
859. Unilateral axillary adenopathy in the setting of COVID-19 vaccination: follow-up: <https://pubmed.ncbi.nlm.nih.gov/34298342/>
860. A systematic review of cases of CNS demyelination following COVID-19 vaccination: <https://pubmed.ncbi.nlm.nih.gov/34839149/>
861. Supraclavicular lymphadenopathy after COVID-19 vaccination: an increasing presentation in the two-week wait neck lump clinic: <https://pubmed.ncbi.nlm.nih.gov/33685772/>
862. COVID-19 vaccine-related axillary and cervical lymphadenopathy in patients with current or previous breast cancer and other malignancies: cross-sectional imaging findings on MRI, CT and PET-CT: <https://pubmed.ncbi.nlm.nih.gov/34719892/>
863. Adenopathy after COVID-19 vaccination: <https://pubmed.ncbi.nlm.nih.gov/33625299/>
864. Incidence of axillary adenopathy on breast imaging after vaccination with COVID-19: <https://pubmed.ncbi.nlm.nih.gov/34292295/>
865. COVID-19 vaccination and lower cervical lymphadenopathy in two-week neck lump clinic: a follow-up audit: <https://pubmed.ncbi.nlm.nih.gov/33947605/>
866. Cervical lymphadenopathy after coronavirus disease vaccination 2019: clinical features and implications for head and neck cancer services: <https://pubmed.ncbi.nlm.nih.gov/34526175/>
867. Lymphadenopathy associated with the COVID-19 vaccine: <https://pubmed.ncbi.nlm.nih.gov/33786231/>
868. Evolution of lymphadenopathy on PET/MRI after COVID-19 vaccination: <https://pubmed.ncbi.nlm.nih.gov/33625301/>
869. Autoimmune hepatitis triggered by SARS-CoV-2 vaccination: <https://pubmed.ncbi.nlm.nih.gov/34332438/>
870. New-onset nephrotic syndrome after Janssen COVID-19 vaccination: case report and literature review: <https://pubmed.ncbi.nlm.nih.gov/34342187/>

871. Massive cervical lymphadenopathy following vaccination with COVID-19: <https://pubmed.ncbi.nlm.nih.gov/34601889/>
872. ANCA glomerulonephritis following Modern COVID-19 vaccination: <https://pubmed.ncbi.nlm.nih.gov/34081948/>
873. Month 1 lessons: extensive longitudinal transverse myelitis following AstraZeneca COVID-19 vaccination: <https://pubmed.ncbi.nlm.nih.gov/34507942/>.
874. Systemic capillary extravasation syndrome after vaccination with ChAdOx1 nCoV-19 (Oxford-AstraZeneca): <https://pubmed.ncbi.nlm.nih.gov/34362727/>
875. Unilateral axillary lymphadenopathy related to COVID-19 vaccine: pattern on screening breast MRI allowing benign evaluation: <https://pubmed.ncbi.nlm.nih.gov/34325221/>
876. Axillary lymphadenopathy in patients with recent Covid-19 vaccination: a new diagnostic dilemma: <https://pubmed.ncbi.nlm.nih.gov/34825530/>.
877. Minimal change disease and acute kidney injury after Pfizer-BioNTech COVID-19 vaccine: <https://pubmed.ncbi.nlm.nih.gov/34000278/>
878. COVID-19 vaccine-induced unilateral axillary adenopathy: follow-up evaluation in the USA: <https://pubmed.ncbi.nlm.nih.gov/34655312/>.
879. Gastroparesis after Pfizer-BioNTech COVID-19 vaccination: <https://pubmed.ncbi.nlm.nih.gov/34187985/>.
880. Abbate, A., Gavin, J., Madanchi, N., Kim, C., Shah, P. R., Klein, K., . . . Danielides, S. (2021). Fulminant myocarditis and systemic hyperinflammation temporally associated with BNT162b2 mRNA COVID-19 vaccination in two patients. *Int J Cardiol*, 340, 119-121. doi:10.1016/j.ijcard.2021.08.018. <https://www.ncbi.nlm.nih.gov/pubmed/34416319>
881. Abu Mouch, S., Roguin, A., Hellou, E., Ishai, A., Shoshan, U., Mahamid, L., . . . Berar Yanay, N. (2021). Myocarditis following COVID-19 mRNA vaccination. *Vaccine*, 39(29), 3790-3793. doi:10.1016/j.vaccine.2021.05.087. <https://www.ncbi.nlm.nih.gov/pubmed/34092429>
882. Albert, E., Aurigemma, G., Saucedo, J., & Gerson, D. S. (2021). Myocarditis following COVID-19 vaccination. *Radiol Case Rep*, 16(8), 2142-2145. doi:10.1016/j.radcr.2021.05.033. <https://www.ncbi.nlm.nih.gov/pubmed/34025885>
883. Aye, Y. N., Mai, A. S., Zhang, A., Lim, O. Z. H., Lin, N., Ng, C. H., . . . Chew, N. W. S. (2021). Acute Myocardial Infarction and Myocarditis following COVID-19 Vaccination. *QJM*. doi:10.1093/qjmed/hcab252. <https://www.ncbi.nlm.nih.gov/pubmed/34586408>
884. Azir, M., Inman, B., Webb, J., & Tannenbaum, L. (2021). STEMI Mimic: Focal Myocarditis in an Adolescent Patient After mRNA COVID-19 Vaccine. *J Emerg Med*, 61(6), e129-e132. doi:10.1016/j.jemermed.2021.09.017. <https://www.ncbi.nlm.nih.gov/pubmed/34756746>
885. Barda, N., Dagan, N., Ben-Shlomo, Y., Kepten, E., Waxman, J., Ohana, R., . . . Balicer, R. D. (2021). Safety of the BNT162b2 mRNA Covid-19 Vaccine in a Nationwide Setting. *N Engl J Med*, 385(12), 1078-1090. doi:10.1056/NEJMoa2110475. <https://www.ncbi.nlm.nih.gov/pubmed/34432976>
886. Bhandari, M., Pradhan, A., Vishwakarma, P., & Sethi, R. (2021). Coronavirus and cardiovascular manifestations- getting to the heart of the matter. *World J Cardiol*, 13(10), 556-565. doi:10.4330/wjc.v13.i10.556. <https://www.ncbi.nlm.nih.gov/pubmed/34754400>
887. Bozkurt, B., Kamat, I., & Hotez, P. J. (2021). Myocarditis With COVID-19 mRNA Vaccines. *Circulation*, 144(6), 471-484.

- doi:10.1161/CIRCULATIONAHA.121.056135. <https://www.ncbi.nlm.nih.gov/pubmed/34281357>
888. Buchhorn, R., Meyer, C., Schulze-Forster, K., Junker, J., & Heidecke, H. (2021). Autoantibody Release in Children after Corona Virus mRNA Vaccination: A Risk Factor of Multisystem Inflammatory Syndrome? *Vaccines (Basel)*, 9(11). doi:10.3390/vaccines9111353. <https://www.ncbi.nlm.nih.gov/pubmed/34835284>
889. Calcaterra, G., Bassareo, P. P., Barilla, F., Romeo, F., & Mehta, J. L. (2022). Concerning the unexpected prothrombotic state following some coronavirus disease 2019 vaccines. *J Cardiovasc Med (Hagerstown)*, 23(2), 71-74. doi:10.2459/JCM.0000000000001232. <https://www.ncbi.nlm.nih.gov/pubmed/34366403>
890. Calcaterra, G., Mehta, J. L., de Gregorio, C., Butera, G., Neroni, P., Fanos, V., & Bassareo, P. P. (2021). COVID 19 Vaccine for Adolescents. Concern about Myocarditis and Pericarditis. *Pediatr Rep*, 13(3), 530-533. doi:10.3390/pediatric13030061. <https://www.ncbi.nlm.nih.gov/pubmed/34564344>
891. Chai, Q., Nygaard, U., Schmidt, R. C., Zaremba, T., Moller, A. M., & Thorvig, C. M. (2022). Multisystem inflammatory syndrome in a male adolescent after his second Pfizer-BioNTech COVID-19 vaccine. *Acta Paediatr*, 111(1), 125-127. doi:10.1111/apa.16141. <https://www.ncbi.nlm.nih.gov/pubmed/34617315>
892. Chamling, B., Vehof, V., Drakos, S., Weil, M., Stalling, P., Vahlhaus, C., . . . Yilmaz, A. (2021). Occurrence of acute infarct-like myocarditis following COVID-19 vaccination: just an accidental co-occurrence or rather vaccination-associated autoimmune myocarditis? *Clin Res Cardiol*, 110(11), 1850-1854. doi:10.1007/s00392-021-01916-w. <https://www.ncbi.nlm.nih.gov/pubmed/34333695>
893. Chang, J. C., & Hawley, H. B. (2021). Vaccine-Associated Thrombocytopenia and Thrombosis: Venous Endotheliopathy Leading to Venous Combined Micro-Macrothrombosis. *Medicina (Kaunas)*, 57(11). doi:10.3390/medicina57111163. <https://www.ncbi.nlm.nih.gov/pubmed/34833382>
894. Chelala, L., Jeudy, J., Hossain, R., Rosenthal, G., Pietris, N., & White, C. (2021). Cardiac MRI Findings of Myocarditis After COVID-19 mRNA Vaccination in Adolescents. *AJR Am J Roentgenol*. doi:10.2214/AJR.21.26853. <https://www.ncbi.nlm.nih.gov/pubmed/34704459>
895. Choi, S., Lee, S., Seo, J. W., Kim, M. J., Jeon, Y. H., Park, J. H., . . . Yeo, N. S. (2021). Myocarditis-induced Sudden Death after BNT162b2 mRNA COVID-19 Vaccination in Korea: Case Report Focusing on Histopathological Findings. *J Korean Med Sci*, 36(40), e286. doi:10.3346/jkms.2021.36.e286. <https://www.ncbi.nlm.nih.gov/pubmed/34664804>
896. Chouchana, L., Blet, A., Al-Khalaf, M., Kafil, T. S., Nair, G., Robblee, J., . . . Liu, P. P. (2021). Features of Inflammatory Heart Reactions Following mRNA COVID-19 Vaccination at a Global Level. *Clin Pharmacol Ther*. doi:10.1002/cpt.2499. <https://www.ncbi.nlm.nih.gov/pubmed/34860360>
897. Chua, G. T., Kwan, M. Y. W., Chui, C. S. L., Smith, R. D., Cheung, E. C., Tian, T., . . . Ip, P. (2021). Epidemiology of Acute Myocarditis/Pericarditis in Hong Kong Adolescents Following Comirnaty Vaccination. *Clin Infect Dis*. doi:10.1093/cid/ciab989. <https://www.ncbi.nlm.nih.gov/pubmed/34849657>
898. Clarke, R., & Ioannou, A. (2021). Should T2 mapping be used in cases of recurrent myocarditis to differentiate between the acute inflammation and chronic scar? *J Pediatr*. doi:10.1016/j.jpeds.2021.12.026. <https://www.ncbi.nlm.nih.gov/pubmed/34933012>
899. Colaneri, M., De Filippo, M., Licari, A., Marseglia, A., Maiocchi, L., Ricciardi, A., . . . Bruno, R. (2021). COVID vaccination and asthma exacerbation: might there be a

- link? *Int J Infect Dis*, 112, 243-246.
doi:10.1016/j.ijid.2021.09.026. <https://www.ncbi.nlm.nih.gov/pubmed/34547487>
900. Das, B. B., Kohli, U., Ramachandran, P., Nguyen, H. H., Greil, G., Hussain, T., . . . Khan, D. (2021). Myopericarditis after messenger RNA Coronavirus Disease 2019 Vaccination in Adolescents 12 to 18 Years of Age. *J Pediatr*, 238, 26-32 e21.
doi:10.1016/j.jpeds.2021.07.044. <https://www.ncbi.nlm.nih.gov/pubmed/34339728>
901. Das, B. B., Moskowitz, W. B., Taylor, M. B., & Palmer, A. (2021). Myocarditis and Pericarditis Following mRNA COVID-19 Vaccination: What Do We Know So Far? *Children (Basel)*, 8(7).
doi:10.3390/children8070607. <https://www.ncbi.nlm.nih.gov/pubmed/34356586>
902. Deb, A., Abdelmalek, J., Iwuji, K., & Nugent, K. (2021). Acute Myocardial Injury Following COVID-19 Vaccination: A Case Report and Review of Current Evidence from Vaccine Adverse Events Reporting System Database. *J Prim Care Community Health*, 12, 21501327211029230.
doi:10.1177/21501327211029230. <https://www.ncbi.nlm.nih.gov/pubmed/34219532>
903. Dickey, J. B., Albert, E., Badr, M., Laraja, K. M., Sena, L. M., Gerson, D. S., . . . Aurigemma, G. P. (2021). A Series of Patients With Myocarditis Following SARS-CoV-2 Vaccination With mRNA-1279 and BNT162b2. *JACC Cardiovasc Imaging*, 14(9), 1862-1863.
doi:10.1016/j.jcmg.2021.06.003. <https://www.ncbi.nlm.nih.gov/pubmed/34246585>
904. Dimopoulou, D., Spyridis, N., Vartzelis, G., Tsolia, M. N., & Maritsi, D. N. (2021). Safety and tolerability of the COVID-19 mRNA-vaccine in adolescents with juvenile idiopathic arthritis on treatment with TNF-inhibitors. *Arthritis Rheumatol*.
doi:10.1002/art.41977. <https://www.ncbi.nlm.nih.gov/pubmed/34492161>
905. Dimopoulou, D., Vartzelis, G., Dasoula, F., Tsolia, M., & Maritsi, D. (2021). Immunogenicity of the COVID-19 mRNA vaccine in adolescents with juvenile idiopathic arthritis on treatment with TNF inhibitors. *Ann Rheum Dis*.
doi:10.1136/annrheumdis-2021221607. <https://www.ncbi.nlm.nih.gov/pubmed/34844930>
906. Ehrlich, P., Klingel, K., Ohlmann-Knafo, S., Huttinger, S., Sood, N., Pickuth, D., & Kindermann, M. (2021). Biopsy-proven lymphocytic myocarditis following first mRNA COVID-19 vaccination in a 40-year-old male: case report. *Clin Res Cardiol*, 110(11), 1855-1859. doi:10.1007/s00392-021-01936-6. <https://www.ncbi.nlm.nih.gov/pubmed/34487236>
907. El Sahly, H. M., Baden, L. R., Essink, B., Doblecki-Lewis, S., Martin, J. M., Anderson, E. J., . . . Group, C. S. (2021). Efficacy of the mRNA-1273 SARS-CoV-2 Vaccine at Completion of Blinded Phase. *N Engl J Med*, 385(19), 1774-1785.
doi:10.1056/NEJMoA2113017. <https://www.ncbi.nlm.nih.gov/pubmed/34551225>
908. Facetti, S., Giraldi, M., Vecchi, A. L., Rogiani, S., & Nassiacos, D. (2021). [Acute myocarditis in a young adult two days after Pfizer vaccination]. *G Ital Cardiol (Rome)*, 22(11), 891-893.
doi:10.1714/3689.36746. <https://www.ncbi.nlm.nih.gov/pubmed/34709227>
909. Fazlollahi, A., Zahmatyar, M., Noori, M., Nejadghaderi, S. A., Sullman, M. J. M., Shekarriz-Foumani, R., . . . Safiri, S. (2021). Cardiac complications following mRNA COVID-19 vaccines: A systematic review of case reports and case series. *Rev Med Virol*, e2318. doi:10.1002/rmv.2318. <https://www.ncbi.nlm.nih.gov/pubmed/34921468>
910. Fazolo, T., Lima, K., Fontoura, J. C., de Souza, P. O., Hilario, G., Zorzetto, R., . . . Bonorino, C. (2021). Pediatric COVID-19 patients in South Brazil show abundant viral mRNA and strong specific anti-viral responses. *Nat Commun*, 12(1), 6844.
doi:10.1038/s41467-021-27120-y. <https://www.ncbi.nlm.nih.gov/pubmed/34824230>

911. Fikenzer, S., & Laufs, U. (2021). Correction to: Response to Letter to the editors referring to Fikenzer, S., Uhe, T., Lavall, D., Rudolph, U., Falz, R., Busse, M., Hepp, P., & Laufs, U. (2020). Effects of surgical and FFP2/N95 face masks on cardiopulmonary exercise capacity. *Clinical research in cardiology: official journal of the German Cardiac Society*, 1-9. Advance online publication. <https://doi.org/10.1007/s00392-020-01704-y>. *Clin Res Cardiol*, 110(8), 1352. doi:10.1007/s00392-021-01896-x. <https://www.ncbi.nlm.nih.gov/pubmed/34170372>
912. Foltran, D., Delmas, C., Flumian, C., De Paoli, P., Salvo, F., Gautier, S., . . . Montastruc, F. (2021). Myocarditis and Pericarditis in Adolescents after First and Second doses of mRNA COVID-19 Vaccines. *Eur Heart J Qual Care Clin Outcomes*. doi:10.1093/ehjqcc/qcab090. <https://www.ncbi.nlm.nih.gov/pubmed/34849667>
913. Forgacs, D., Jang, H., Abreu, R. B., Hanley, H. B., Gattiker, J. L., Jefferson, A. M., & Ross, T. M. (2021). SARS-CoV-2 mRNA Vaccines Elicit Different Responses in Immunologically Naive and Pre-Immune Humans. *Front Immunol*, 12, 728021. doi:10.3389/fimmu.2021.728021. <https://www.ncbi.nlm.nih.gov/pubmed/34646267>
914. Furer, V., Eviatar, T., Zisman, D., Peleg, H., Paran, D., Levartovsky, D., . . . Elkayam, O. (2021). Immunogenicity and safety of the BNT162b2 mRNA COVID-19 vaccine in adult patients with autoimmune inflammatory rheumatic diseases and in the general population: a multicentre study. *Ann Rheum Dis*, 80(10), 1330-1338. doi:10.1136/annrheumdis-2021-220647. <https://www.ncbi.nlm.nih.gov/pubmed/34127481>
915. Galindo, R., Chow, H., & Rongkavilit, C. (2021). COVID-19 in Children: Clinical Manifestations and Pharmacologic Interventions Including Vaccine Trials. *Pediatr Clin North Am*, 68(5), 961-976. doi:10.1016/j.pcl.2021.05.004. <https://www.ncbi.nlm.nih.gov/pubmed/34538306>
916. Gargano, J. W., Wallace, M., Hadler, S. C., Langley, G., Su, J. R., Oster, M. E., . . . Oliver, S. E. (2021). Use of mRNA COVID-19 Vaccine After Reports of Myocarditis Among Vaccine Recipients: Update from the Advisory Committee on Immunization Practices – United States, June 2021. *MMWR Morb Mortal Wkly Rep*, 70(27), 977-982. doi:10.15585/mmwr.mm7027e2. <https://www.ncbi.nlm.nih.gov/pubmed/34237049>
917. Gatti, M., Raschi, E., Moretti, U., Ardizzoni, A., Poluzzi, E., & Diemberger, I. (2021). Influenza Vaccination and Myo-Pericarditis in Patients Receiving Immune Checkpoint Inhibitors: Investigating the Likelihood of Interaction through the Vaccine Adverse Event Reporting System and VigiBase. *Vaccines (Basel)*, 9(1). doi:10.3390/vaccines9010019. <https://www.ncbi.nlm.nih.gov/pubmed/33406694>
918. Gautam, N., Saluja, P., Fudim, M., Jambhekar, K., Pandey, T., & Al'Aref, S. (2021). A Late Presentation of COVID-19 Vaccine-Induced Myocarditis. *Cureus*, 13(9), e17890. doi:10.7759/cureus.17890. <https://www.ncbi.nlm.nih.gov/pubmed/34660088>
919. Gellad, W. F. (2021). Myocarditis after vaccination against covid-19. *BMJ*, 375, n3090. doi:10.1136/bmj.n3090. <https://www.ncbi.nlm.nih.gov/pubmed/34916217>
920. Greenhawt, M., Abrams, E. M., Shaker, M., Chu, D. K., Khan, D., Akin, C., . . . Golden, D. B. K. (2021). The Risk of Allergic Reaction to SARS-CoV-2 Vaccines and Recommended Evaluation and Management: A Systematic Review, Meta-Analysis, GRADE Assessment, and International Consensus Approach. *J Allergy Clin Immunol Pract*, 9(10), 3546-3567. doi:10.1016/j.jaip.2021.06.006. <https://www.ncbi.nlm.nih.gov/pubmed/34153517>
921. Haaf, P., Kuster, G. M., Mueller, C., Berger, C. T., Monney, P., Burger, P., . . . Tanner, F. C. (2021). The very low risk of myocarditis and pericarditis after mRNA

- COVID-19 vaccination should not discourage vaccination. *Swiss Med Wkly*, 151, w30087.
doi:10.4414/smw.2021.w30087. <https://www.ncbi.nlm.nih.gov/pubmed/34668687>
922. Hasnie, A. A., Hasnie, U. A., Patel, N., Aziz, M. U., Xie, M., Lloyd, S. G., & Prabhu, S. D. (2021). Perimyocarditis following first dose of the mRNA-1273 SARS-CoV-2 (Moderna) vaccine in a healthy young male: a case report. *BMC Cardiovasc Disord*, 21(1), 375. doi:10.1186/s12872-021-02183-3. <https://www.ncbi.nlm.nih.gov/pubmed/34348657>
923. Hause, A. M., Gee, J., Baggs, J., Abara, W. E., Marquez, P., Thompson, D., . . . Shay, D. K. (2021). COVID-19 Vaccine Safety in Adolescents Aged 12-17 Years – United States, December 14, 2020-July 16, 2021. *MMWR Morb Mortal Wkly Rep*, 70(31), 1053-1058.
doi:10.15585/mmwr.mm7031e1. <https://www.ncbi.nlm.nih.gov/pubmed/34351881>
924. Helms, J. M., Ansteatt, K. T., Roberts, J. C., Kamatam, S., Foong, K. S., Labayog, J. S., & Tarantino, M. D. (2021). Severe, Refractory Immune Thrombocytopenia Occurring After SARS-CoV-2 Vaccine. *J Blood Med*, 12, 221-224.
doi:10.2147/JBM.S307047. <https://www.ncbi.nlm.nih.gov/pubmed/33854395>
925. Hippisley-Cox, J., Patone, M., Mei, X. W., Saatci, D., Dixon, S., Khunti, K., . . . Coupland, C. A. C. (2021). Risk of thrombocytopenia and thromboembolism after covid-19 vaccination and SARS-CoV-2 positive testing: self-controlled case series study. *BMJ*, 374, n1931.
doi:10.1136/bmj.n1931. <https://www.ncbi.nlm.nih.gov/pubmed/34446426>
926. Ho, J. S., Sia, C. H., Ngiam, J. N., Loh, P. H., Chew, N. W., Kong, W. K., & Poh, K. K. (2021). A review of COVID-19 vaccination and the reported cardiac manifestations. *Singapore Med J*.
doi:10.11622/smedj.2021210. <https://www.ncbi.nlm.nih.gov/pubmed/34808708>
927. Iguchi, T., Umeda, H., Kojima, M., Kanno, Y., Tanaka, Y., Kinoshita, N., & Sato, D. (2021). Cumulative Adverse Event Reporting of Anaphylaxis After mRNA COVID-19 Vaccine (Pfizer-BioNTech) Injections in Japan: The First-Month Report. *Drug Saf*, 44(11), 1209-1214. doi:10.1007/s40264-021-01104-9. <https://www.ncbi.nlm.nih.gov/pubmed/34347278>
928. In brief: Myocarditis with the Pfizer/BioNTech and Moderna COVID-19 vaccines. (2021). *Med Lett Drugs Ther*, 63(1629), e9. Retrieved from <https://www.ncbi.nlm.nih.gov/pubmed/34544112>
<https://www.ncbi.nlm.nih.gov/pubmed/34544112>
929. Ioannou, A. (2021a). Myocarditis should be considered in those with a troponin rise and unobstructed coronary arteries following Pfizer-BioNTech COVID-19 vaccination. *QJM*.
doi:10.1093/qjmed/hcab231. <https://www.ncbi.nlm.nih.gov/pubmed/34463755>
930. Ioannou, A. (2021b). T2 mapping should be utilised in cases of suspected myocarditis to confirm an acute inflammatory process. *QJM*.
doi:10.1093/qjmed/hcab326. <https://www.ncbi.nlm.nih.gov/pubmed/34931681>
931. Isaak, A., Feisst, A., & Luetkens, J. A. (2021). Myocarditis Following COVID-19 Vaccination. *Radiology*, 301(1), E378-E379.
doi:10.1148/radiol.2021211766. <https://www.ncbi.nlm.nih.gov/pubmed/34342500>
932. Istampoulouoglou, I., Dimitriou, G., Spani, S., Christ, A., Zimmermanns, B., Koechlin, S., . . . Leuppi-Taegtmeier, A. B. (2021). Myocarditis and pericarditis in association with COVID-19 mRNA-vaccination: cases from a regional pharmacovigilance centre. *Glob Cardiol Sci Pract*, 2021(3), e202118.
doi:10.21542/gcsp.2021.18. <https://www.ncbi.nlm.nih.gov/pubmed/34805376>

933. Jaafar, R., Boschi, C., Aherfi, S., Bancod, A., Le Bideau, M., Edouard, S., . . . La Scola, B. (2021). High Individual Heterogeneity of Neutralizing Activities against the Original Strain and Nine Different Variants of SARS-CoV-2. *Viruses*, *13*(11). doi:10.3390/v13112177. <https://www.ncbi.nlm.nih.gov/pubmed/34834983>
934. Jain, S. S., Steele, J. M., Fonseca, B., Huang, S., Shah, S., Maskatia, S. A., . . . Grosse-Wortmann, L. (2021). COVID-19 Vaccination-Associated Myocarditis in Adolescents. *Pediatrics*, *148*(5). doi:10.1542/peds.2021-053427. <https://www.ncbi.nlm.nih.gov/pubmed/34389692>
935. Jhaveri, R., Adler-Shohet, F. C., Blyth, C. C., Chiotos, K., Gerber, J. S., Green, M., . . . Zaoutis, T. (2021). Weighing the Risks of Perimyocarditis With the Benefits of SARS-CoV-2 mRNA Vaccination in Adolescents. *J Pediatric Infect Dis Soc*, *10*(10), 937-939. doi:10.1093/jpids/piab061. <https://www.ncbi.nlm.nih.gov/pubmed/34270752>
936. Kaneta, K., Yokoi, K., Jojima, K., Kotooka, N., & Node, K. (2021). Young Male With Myocarditis Following mRNA-1273 Vaccination Against Coronavirus Disease-2019 (COVID-19). *Circ J*. doi:10.1253/circj.CJ-21-0818. <https://www.ncbi.nlm.nih.gov/pubmed/34744118>
937. Kaul, R., Sreenivasan, J., Goel, A., Malik, A., Bandyopadhyay, D., Jin, C., . . . Panza, J. A. (2021). Myocarditis following COVID-19 vaccination. *Int J Cardiol Heart Vasc*, *36*, 100872. doi:10.1016/j.ijcha.2021.100872. <https://www.ncbi.nlm.nih.gov/pubmed/34568540>
938. Khogali, F., & Abdelrahman, R. (2021). Unusual Presentation of Acute Perimyocarditis Following SARS-COV-2 mRNA-1237 Moderna Vaccination. *Cureus*, *13*(7), e16590. doi:10.7759/cureus.16590. <https://www.ncbi.nlm.nih.gov/pubmed/34447639>
939. Kim, H. W., Jenista, E. R., Wendell, D. C., Azevedo, C. F., Campbell, M. J., Darty, S. N., . . . Kim, R. J. (2021). Patients With Acute Myocarditis Following mRNA COVID-19 Vaccination. *JAMA Cardiol*, *6*(10), 1196-1201. doi:10.1001/jamacardio.2021.2828. <https://www.ncbi.nlm.nih.gov/pubmed/34185046>
940. Kim, I. C., Kim, H., Lee, H. J., Kim, J. Y., & Kim, J. Y. (2021). Cardiac Imaging of Acute Myocarditis Following COVID-19 mRNA Vaccination. *J Korean Med Sci*, *36*(32), e229. doi:10.3346/jkms.2021.36.e229. <https://www.ncbi.nlm.nih.gov/pubmed/34402228>
941. King, W. W., Petersen, M. R., Matar, R. M., Budweg, J. B., Cuervo Pardo, L., & Petersen, J. W. (2021). Myocarditis following mRNA vaccination against SARS-CoV-2, a case series. *Am Heart J Plus*, *8*, 100042. doi:10.1016/j.ahjo.2021.100042. <https://www.ncbi.nlm.nih.gov/pubmed/34396358>
- Klein, N. P., Lewis, N., Goddard, K., Fireman, B., Zerbo, O., Hanson, K. E., . . . Weintraub, E. S. (2021). Surveillance for Adverse Events After COVID-19 mRNA Vaccination. *JAMA*, *326*(14), 1390-1399. doi:10.1001/jama.2021.15072. <https://www.ncbi.nlm.nih.gov/pubmed/34477808>
942. Klimek, L., Bergmann, K. C., Brehler, R., Pflutzner, W., Zuberbier, T., Hartmann, K., . . . Worm, M. (2021). Practical handling of allergic reactions to COVID-19 vaccines: A position paper from German and Austrian Allergy Societies AeDA, DGAKI, GPA and OGAI. *Allergo J Int*, 1-17. doi:10.1007/s40629-021-00165-7. <https://www.ncbi.nlm.nih.gov/pubmed/33898162>
943. Klimek, L., Novak, N., Hamelmann, E., Werfel, T., Wagenmann, M., Taube, C., . . . Worm, M. (2021). Severe allergic reactions after COVID-19 vaccination with the Pfizer/BioNTech vaccine in Great Britain and USA: Position statement of the German Allergy Societies: Medical Association of German Allergologists (AeDA), German

- Society for Allergology and Clinical Immunology (DGAKI) and Society for Pediatric Allergology and Environmental Medicine (GPA). *Allergo J Int*, 30(2), 51-55.
doi:10.1007/s40629-020-00160-4. <https://www.ncbi.nlm.nih.gov/pubmed/33643776>
944. Kohli, U., Desai, L., Chowdhury, D., Harahsheh, A. S., Yonts, A. B., Ansong, A., . . . Ang, J. Y. (2021). mRNA Coronavirus-19 Vaccine-Associated Myopericarditis in Adolescents: A Survey Study. *J Pediatr*.
doi:10.1016/j.jpeds.2021.12.025. <https://www.ncbi.nlm.nih.gov/pubmed/34952008>
945. Kostoff, R. N., Calina, D., Kanduc, D., Briggs, M. B., Vlachoyiannopoulos, P., Svistunov, A. A., & Tsatsakis, A. (2021a). Erratum to “Why are we vaccinating children against COVID-19?” [Toxicol. Rep. 8C (2021) 1665-1684 / 1193]. *Toxicol Rep*, 8, 1981.
doi:10.1016/j.toxrep.2021.10.003. <https://www.ncbi.nlm.nih.gov/pubmed/34642628>
946. Kostoff, R. N., Calina, D., Kanduc, D., Briggs, M. B., Vlachoyiannopoulos, P., Svistunov, A. A., & Tsatsakis, A. (2021b). Why are we vaccinating children against COVID-19? *Toxicol Rep*, 8, 1665-1684.
doi:10.1016/j.toxrep.2021.08.010. <https://www.ncbi.nlm.nih.gov/pubmed/34540594>
947. Kremsner, P. G., Mann, P., Kroidl, A., Leroux-Roels, I., Schindler, C., Gabor, J. J., . . . Group, C.-N.-S. (2021). Safety and immunogenicity of an mRNA-lipid nanoparticle vaccine candidate against SARS-CoV-2 : A phase 1 randomized clinical trial. *Wien Klin Wochenschr*, 133(17-18), 931-941. doi:10.1007/s00508-021-01922-y. <https://www.ncbi.nlm.nih.gov/pubmed/34378087>
948. Kustin, T., Harel, N., Finkel, U., Perchik, S., Harari, S., Tahor, M., . . . Stern, A. (2021). Evidence for increased breakthrough rates of SARS-CoV-2 variants of concern in BNT162b2-mRNA-vaccinated individuals. *Nat Med*, 27(8), 1379-1384.
doi:10.1038/s41591-021-01413-7. <https://www.ncbi.nlm.nih.gov/pubmed/34127854>
949. Kwan, M. Y. W., Chua, G. T., Chow, C. B., Tsao, S. S. L., To, K. K. W., Yuen, K. Y., . . . Ip, P. (2021). mRNA COVID vaccine and myocarditis in adolescents. *Hong Kong Med J*, 27(5), 326-327.
doi:10.12809/hkmj215120. <https://www.ncbi.nlm.nih.gov/pubmed/34393110>
950. Lee, E., Chew, N. W. S., Ng, P., & Yeo, T. J. (2021). Reply to “Letter to the editor: Myocarditis should be considered in those with a troponin rise and unobstructed coronary arteries following PfizerBioNTech COVID-19 vaccination”. *QJM*.
doi:10.1093/qjmed/hcab232. <https://www.ncbi.nlm.nih.gov/pubmed/34463770>
951. Lee, E. J., Cines, D. B., Gernsheimer, T., Kessler, C., Michel, M., Tarantino, M. D., . . . Bussel, J. B. (2021). Thrombocytopenia following Pfizer and Moderna SARS-CoV-2 vaccination. *Am J Hematol*, 96(5), 534-537.
doi:10.1002/ajh.26132. <https://www.ncbi.nlm.nih.gov/pubmed/33606296>
952. Levin, D., Shimon, G., Fadlon-Derai, M., Gershovitz, L., Shovali, A., Sebbag, A., . . . Gordon, B. (2021). Myocarditis following COVID-19 vaccination – A case series. *Vaccine*, 39(42), 6195-6200.
doi:10.1016/j.vaccine.2021.09.004. <https://www.ncbi.nlm.nih.gov/pubmed/34535317>
953. Li, J., Hui, A., Zhang, X., Yang, Y., Tang, R., Ye, H., . . . Zhu, F. (2021). Safety and immunogenicity of the SARS-CoV-2 BNT162b1 mRNA vaccine in younger and older Chinese adults: a randomized, placebo-controlled, double-blind phase 1 study. *Nat Med*, 27(6), 1062-1070. doi:10.1038/s41591-021-01330-9. <https://www.ncbi.nlm.nih.gov/pubmed/33888900>
954. Li, M., Yuan, J., Lv, G., Brown, J., Jiang, X., & Lu, Z. K. (2021). Myocarditis and Pericarditis following COVID-19 Vaccination: Inequalities in Age and Vaccine Types. *J Pers Med*, 11(11).
doi:10.3390/jpm11111106. <https://www.ncbi.nlm.nih.gov/pubmed/34834458>

955. Lim, Y., Kim, M. C., Kim, K. H., Jeong, I. S., Cho, Y. S., Choi, Y. D., & Lee, J. E. (2021). Case Report: Acute Fulminant Myocarditis and Cardiogenic Shock After Messenger RNA Coronavirus Disease 2019 Vaccination Requiring Extracorporeal Cardiopulmonary Resuscitation. *Front Cardiovasc Med*, 8, 758996. doi:10.3389/fcvm.2021.758996. <https://www.ncbi.nlm.nih.gov/pubmed/34778411>
956. Long, S. S. (2021). Important Insights into Myopericarditis after the Pfizer mRNA COVID-19 Vaccination in Adolescents. *J Pediatr*, 238, 5. doi:10.1016/j.jpeds.2021.07.057. <https://www.ncbi.nlm.nih.gov/pubmed/34332972>
957. Luk, A., Clarke, B., Dahdah, N., Ducharme, A., Krahn, A., McCrindle, B., . . . McDonald, M. (2021). Myocarditis and Pericarditis After COVID-19 mRNA Vaccination: Practical Considerations for Care Providers. *Can J Cardiol*, 37(10), 1629-1634. doi:10.1016/j.cjca.2021.08.001. <https://www.ncbi.nlm.nih.gov/pubmed/34375696>
958. Madelon, N., Lauper, K., Breville, G., Sabater Royo, I., Goldstein, R., Andrey, D. O., . . . Eberhardt, C. S. (2021). Robust T cell responses in anti-CD20 treated patients following COVID-19 vaccination: a prospective cohort study. *Clin Infect Dis*. doi:10.1093/cid/ciab954. <https://www.ncbi.nlm.nih.gov/pubmed/34791081>
959. Mangat, C., & Milosavljevic, N. (2021). BNT162b2 Vaccination during Pregnancy Protects Both the Mother and Infant: Anti-SARS-CoV-2 S Antibodies Persistently Positive in an Infant at 6 Months of Age. *Case Rep Pediatr*, 2021, 6901131. doi:10.1155/2021/6901131. <https://www.ncbi.nlm.nih.gov/pubmed/34676123>
960. Mark, C., Gupta, S., Punnett, A., Upton, J., Orkin, J., Atkinson, A., . . . Alexander, S. (2021). Safety of administration of BNT162b2 mRNA (Pfizer-BioNTech) COVID-19 vaccine in youths and young adults with a history of acute lymphoblastic leukemia and allergy to PEG-asparaginase. *Pediatr Blood Cancer*, 68(11), e29295. doi:10.1002/pbc.29295. <https://www.ncbi.nlm.nih.gov/pubmed/34398511>
961. Martins-Filho, P. R., Quintans-Junior, L. J., de Souza Araujo, A. A., Sposato, K. B., Souza Tavares, C. S., Gurgel, R. Q., . . . Santos, V. S. (2021). Socio-economic inequalities and COVID-19 incidence and mortality in Brazilian children: a nationwide register-based study. *Public Health*, 190, 4-6. doi:10.1016/j.puhe.2020.11.005. <https://www.ncbi.nlm.nih.gov/pubmed/33316478>
962. McLean, K., & Johnson, T. J. (2021). Myopericarditis in a previously healthy adolescent male following COVID-19 vaccination: A case report. *Acad Emerg Med*, 28(8), 918-921. doi:10.1111/acem.14322. <https://www.ncbi.nlm.nih.gov/pubmed/34133825>
963. Mevorach, D., Anis, E., Cedar, N., Bromberg, M., Haas, E. J., Nadir, E., . . . Alroy-Preis, S. (2021). Myocarditis after BNT162b2 mRNA Vaccine against Covid-19 in Israel. *N Engl J Med*, 385(23), 2140-2149. doi:10.1056/NEJMoa2109730. <https://www.ncbi.nlm.nih.gov/pubmed/34614328>
964. Minocha, P. K., Better, D., Singh, R. K., & Hoque, T. (2021). Recurrence of Acute Myocarditis Temporally Associated with Receipt of the mRNA Coronavirus Disease 2019 (COVID-19) Vaccine in a Male Adolescent. *J Pediatr*, 238, 321-323. doi:10.1016/j.jpeds.2021.06.035. <https://www.ncbi.nlm.nih.gov/pubmed/34166671>
965. Mizrahi, B., Lotan, R., Kalkstein, N., Peretz, A., Perez, G., Ben-Tov, A., . . . Patalon, T. (2021). Correlation of SARS-CoV-2-breakthrough infections to time-from-vaccine. *Nat Commun*, 12(1), 6379. doi:10.1038/s41467-021-26672-3. <https://www.ncbi.nlm.nih.gov/pubmed/34737312>
966. Moffitt, K., Cheung, E., Yeung, T., Stamoulis, C., & Malley, R. (2021). Analysis of Staphylococcus aureus Transcriptome in Pediatric Soft Tissue Abscesses and Comparison to Murine Infections. *Infect Immun*, 89(4). doi:10.1128/IAI.00715-20. <https://www.ncbi.nlm.nih.gov/pubmed/33526560>

967. Mohamed, L., Madsen, A. M. R., Schaltz-Buchholzer, F., Ostefeld, A., Netea, M. G., Benn, C. S., & Kofoed, P. E. (2021). Reactivation of BCG vaccination scars after vaccination with mRNA-Covid-vaccines: two case reports. *BMC Infect Dis*, *21*(1), 1264. doi:10.1186/s12879-021-06949-0. <https://www.ncbi.nlm.nih.gov/pubmed/34930152>
968. Montgomery, J., Ryan, M., Engler, R., Hoffman, D., McClenathan, B., Collins, L., . . . Cooper, L. T., Jr. (2021). Myocarditis Following Immunization With mRNA COVID-19 Vaccines in Members of the US Military. *JAMA Cardiol*, *6*(10), 1202-1206. doi:10.1001/jamacardio.2021.2833. <https://www.ncbi.nlm.nih.gov/pubmed/34185045>
969. Murakami, Y., Shinohara, M., Oka, Y., Wada, R., Noike, R., Ohara, H., . . . Ikeda, T. (2021). Myocarditis Following a COVID-19 Messenger RNA Vaccination: A Japanese Case Series. *Intern Med*. doi:10.2169/internalmedicine.8731-21. <https://www.ncbi.nlm.nih.gov/pubmed/34840235>
970. Nagasaka, T., Koitabashi, N., Ishibashi, Y., Aihara, K., Takama, N., Ohyama, Y., . . . Kaneko, Y. (2021). Acute Myocarditis Associated with COVID-19 Vaccination: A Case Report. *J Cardiol Cases*. doi:10.1016/j.jccase.2021.11.006. <https://www.ncbi.nlm.nih.gov/pubmed/34876937>
971. Ntouros, P. A., Vlachogiannis, N. I., Pappa, M., Nezos, A., Mavragani, C. P., Tektonidou, M. G., . . . Sfikakis, P. P. (2021). Effective DNA damage response after acute but not chronic immune challenge: SARS-CoV-2 vaccine versus Systemic Lupus Erythematosus. *Clin Immunol*, *229*, 108765. doi:10.1016/j.clim.2021.108765. <https://www.ncbi.nlm.nih.gov/pubmed/34089859>
972. Nygaard, U., Holm, M., Bohnstedt, C., Chai, Q., Schmidt, L. S., Hartling, U. B., . . . Stensballe, L. G. (2022). Population-based Incidence of Myopericarditis After COVID-19 Vaccination in Danish Adolescents. *Pediatr Infect Dis J*, *41*(1), e25-e28. doi:10.1097/INF.0000000000003389. <https://www.ncbi.nlm.nih.gov/pubmed/34889875>
973. Oberhardt, V., Luxenburger, H., Kemming, J., Schulien, I., Ciminski, K., Giese, S., . . . Hofmann, M. (2021). Rapid and stable mobilization of CD8(+) T cells by SARS-CoV-2 mRNA vaccine. *Nature*, *597*(7875), 268-273. doi:10.1038/s41586-021-03841-4. <https://www.ncbi.nlm.nih.gov/pubmed/34320609>
974. Park, H., Yun, K. W., Kim, K. R., Song, S. H., Ahn, B., Kim, D. R., . . . Kim, Y. J. (2021). Epidemiology and Clinical Features of Myocarditis/Pericarditis before the Introduction of mRNA COVID-19 Vaccine in Korean Children: a Multicenter Study. *J Korean Med Sci*, *36*(32), e232. doi:10.3346/jkms.2021.36.e232. <https://www.ncbi.nlm.nih.gov/pubmed/34402230>
975. Park, J., Brekke, D. R., & Bratincsak, A. (2021). Self-limited myocarditis presenting with chest pain and ST segment elevation in adolescents after vaccination with the BNT162b2 mRNA vaccine. *Cardiol Young*, 1-4. doi:10.1017/S1047951121002547. <https://www.ncbi.nlm.nih.gov/pubmed/34180390>
976. Patel, Y. R., Louis, D. W., Atalay, M., Agarwal, S., & Shah, N. R. (2021). Cardiovascular magnetic resonance findings in young adult patients with acute myocarditis following mRNA COVID-19 vaccination: a case series. *J Cardiovasc Magn Reson*, *23*(1), 101. doi:10.1186/s12968-021-00795-4. <https://www.ncbi.nlm.nih.gov/pubmed/34496880>
977. Patone, M., Mei, X. W., Handunnetthi, L., Dixon, S., Zaccardi, F., Shankar-Hari, M., . . . Hippisley-Cox, J. (2021). Risks of myocarditis, pericarditis, and cardiac arrhythmias associated with COVID-19 vaccination or SARS-CoV-2 infection. *Nat Med*. doi:10.1038/s41591-021-01630-0. <https://www.ncbi.nlm.nih.gov/pubmed/34907393>

978. Patrignani, A., Schicchi, N., Calcagnoli, F., Falchetti, E., Ciampani, N., Argalia, G., & Mariani, A. (2021). Acute myocarditis following Comirnaty vaccination in a healthy man with previous SARS-CoV-2 infection. *Radiol Case Rep*, 16(11), 3321-3325.
doi:10.1016/j.radcr.2021.07.082. <https://www.ncbi.nlm.nih.gov/pubmed/34367386>
979. Perez, Y., Levy, E. R., Joshi, A. Y., Virk, A., Rodriguez-Porcel, M., Johnson, M., . . . Swift, M. D. (2021). Myocarditis Following COVID-19 mRNA Vaccine: A Case Series and Incidence Rate Determination. *Clin Infect Dis*.
doi:10.1093/cid/ciab926. <https://www.ncbi.nlm.nih.gov/pubmed/34734240>
980. Perrotta, A., Biondi-Zoccai, G., Saade, W., Miraldi, F., Morelli, A., Marullo, A. G., . . . Peruzzi, M. (2021). A snapshot global survey on side effects of COVID-19 vaccines among healthcare professionals and armed forces with a focus on headache. *Panminerva Med*, 63(3), 324-331. doi:10.23736/S0031-0808.21.04435-9. <https://www.ncbi.nlm.nih.gov/pubmed/34738774>
981. Pinana, J. L., Lopez-Corral, L., Martino, R., Montoro, J., Vazquez, L., Perez, A., . . . Cell Therapy, G. (2022). SARS-CoV-2-reactive antibody detection after SARS-CoV-2 vaccination in hematopoietic stem cell transplant recipients: Prospective survey from the Spanish Hematopoietic Stem Cell Transplantation and Cell Therapy Group. *Am J Hematol*, 97(1), 30-42.
doi:10.1002/ajh.26385. <https://www.ncbi.nlm.nih.gov/pubmed/34695229>
982. Revon-Riviere, G., Ninove, L., Min, V., Rome, A., Coze, C., Verschuur, A., . . . Andre, N. (2021). The BNT162b2 mRNA COVID-19 vaccine in adolescents and young adults with cancer: A monocentric experience. *Eur J Cancer*, 154, 30-34.
doi:10.1016/j.ejca.2021.06.002. <https://www.ncbi.nlm.nih.gov/pubmed/34233234>
983. Sanchez Tijmes, F., Thavendiranathan, P., Udell, J. A., Seidman, M. A., & Hanneman, K. (2021). Cardiac MRI Assessment of Nonischemic Myocardial Inflammation: State of the Art Review and Update on Myocarditis Associated with COVID-19 Vaccination. *Radiol Cardiothorac Imaging*, 3(6), e210252.
doi:10.1148/ryct.210252. <https://www.ncbi.nlm.nih.gov/pubmed/34934954>
984. Schauer, J., Buddhé, S., Colyer, J., Sagiv, E., Law, Y., Mallenahalli Chikkabyrappa, S., & Portman, M. A. (2021). Myopericarditis After the Pfizer Messenger Ribonucleic Acid Coronavirus Disease Vaccine in Adolescents. *J Pediatr*, 238, 317-320.
doi:10.1016/j.jpeds.2021.06.083. <https://www.ncbi.nlm.nih.gov/pubmed/34228985>
985. Schneider, J., Sottmann, L., Greinacher, A., Hagen, M., Kasper, H. U., Kuhnen, C., . . . Schmeling, A. (2021). Postmortem investigation of fatalities following vaccination with COVID-19 vaccines. *Int J Legal Med*, 135(6), 2335-2345. doi:10.1007/s00414-021-02706-9. <https://www.ncbi.nlm.nih.gov/pubmed/34591186>
986. Schramm, R., Costard-Jackle, A., Rivinius, R., Fischer, B., Muller, B., Boeken, U., . . . Gummert, J. (2021). Poor humoral and T-cell response to two-dose SARS-CoV-2 messenger RNA vaccine BNT162b2 in cardiothoracic transplant recipients. *Clin Res Cardiol*, 110(8), 1142-1149. doi:10.1007/s00392-021-01880-5. <https://www.ncbi.nlm.nih.gov/pubmed/34241676>
987. Sessa, F., Salerno, M., Esposito, M., Di Nunno, N., Zamboni, P., & Pomara, C. (2021). Autopsy Findings and Causality Relationship between Death and COVID-19 Vaccination: A Systematic Review. *J Clin Med*, 10(24).
doi:10.3390/jcm10245876. <https://www.ncbi.nlm.nih.gov/pubmed/34945172>
988. Sharif, N., Alzahrani, K. J., Ahmed, S. N., & Dey, S. K. (2021). Efficacy, Immunogenicity and Safety of COVID-19 Vaccines: A Systematic Review and Meta-Analysis. *Front Immunol*, 12, 714170.
doi:10.3389/fimmu.2021.714170. <https://www.ncbi.nlm.nih.gov/pubmed/34707602>

989. Shay, D. K., Gee, J., Su, J. R., Myers, T. R., Marquez, P., Liu, R., . . . Shimabukuro, T. T. (2021). Safety Monitoring of the Janssen (Johnson & Johnson) COVID-19 Vaccine – United States, March-April 2021. *MMWR Morb Mortal Wkly Rep*, 70(18), 680-684.
doi:10.15585/mmwr.mm7018e2. <https://www.ncbi.nlm.nih.gov/pubmed/33956784>
990. Shazley, O., & Alshazley, M. (2021). A COVID-Positive 52-Year-Old Man Presented With Venous Thromboembolism and Disseminated Intravascular Coagulation Following Johnson & Johnson Vaccination: A Case-Study. *Cureus*, 13(7), e16383.
doi:10.7759/cureus.16383. <https://www.ncbi.nlm.nih.gov/pubmed/34408937>
991. Shiyovich, A., Witberg, G., Aviv, Y., Eisen, A., Orvin, K., Wiessman, M., . . . Hamdan, A. (2021). Myocarditis following COVID-19 vaccination: magnetic resonance imaging study. *Eur Heart J Cardiovasc Imaging*.
doi:10.1093/ehjci/jeab230. <https://www.ncbi.nlm.nih.gov/pubmed/34739045>
992. Simone, A., Herald, J., Chen, A., Gulati, N., Shen, A. Y., Lewin, B., & Lee, M. S. (2021). Acute Myocarditis Following COVID-19 mRNA Vaccination in Adults Aged 18 Years or Older. *JAMA Intern Med*, 181(12), 1668-1670.
doi:10.1001/jamainternmed.2021.5511. <https://www.ncbi.nlm.nih.gov/pubmed/34605853>
993. Singer, M. E., Taub, I. B., & Kaelber, D. C. (2021). Risk of Myocarditis from COVID-19 Infection in People Under Age 20: A Population-Based Analysis. *medRxiv*.
doi:10.1101/2021.07.23.21260998. <https://www.ncbi.nlm.nih.gov/pubmed/34341797>
994. Smith, C., Odd, D., Harwood, R., Ward, J., Linney, M., Clark, M., . . . Fraser, L. K. (2021). Deaths in children and young people in England after SARS-CoV-2 infection during the first pandemic year. *Nat Med*. doi:10.1038/s41591-021-01578-1. <https://www.ncbi.nlm.nih.gov/pubmed/34764489>
995. Snapiri, O., Rosenberg Danziger, C., Shirman, N., Weissbach, A., Lowenthal, A., Ayalon, I., . . . Bilavsky, E. (2021). Transient Cardiac Injury in Adolescents Receiving the BNT162b2 mRNA COVID-19 Vaccine. *Pediatr Infect Dis J*, 40(10), e360-e363.
doi:10.1097/INF.0000000000003235. <https://www.ncbi.nlm.nih.gov/pubmed/34077949>
996. Spinner, J. A., Julien, C. L., Olayinka, L., Dreyer, W. J., Bocchini, C. E., Munoz, F. M., & Devaraj, S. (2021). SARS-CoV-2 anti-spike antibodies after vaccination in pediatric heart transplantation: A first report. *J Heart Lung Transplant*.
doi:10.1016/j.healun.2021.11.001. <https://www.ncbi.nlm.nih.gov/pubmed/34911654>
997. Starekova, J., Bluemke, D. A., Bradham, W. S., Grist, T. M., Schiebler, M. L., & Reeder, S. B. (2021). Myocarditis Associated with mRNA COVID-19 Vaccination. *Radiology*, 301(2), E409-E411.
doi:10.1148/radiol.2021211430. <https://www.ncbi.nlm.nih.gov/pubmed/34282971>
998. Sulemankhil, I., Abdelrahman, M., & Negi, S. I. (2021). Temporal association between the COVID-19 Ad26.COV2.S vaccine and acute myocarditis: A case report and literature review. *Cardiovasc Revasc Med*.
doi:10.1016/j.carrev.2021.08.012. <https://www.ncbi.nlm.nih.gov/pubmed/34420869>
999. Tailor, P. D., Feighery, A. M., El-Sabawi, B., & Prasad, A. (2021). Case report: acute myocarditis following the second dose of mRNA-1273 SARS-CoV-2 vaccine. *Eur Heart J Case Rep*, 5(8), ytab319.
doi:10.1093/ehjcr/ytab319. <https://www.ncbi.nlm.nih.gov/pubmed/34514306>
1000. Takeda, M., Ishio, N., Shoji, T., Mori, N., Matsumoto, M., & Shikama, N. (2021). Eosinophilic Myocarditis Following Coronavirus Disease 2019 (COVID-19)

- Vaccination. *Circ J*. doi:10.1253/circj.CJ-21-0935. <https://www.ncbi.nlm.nih.gov/pubmed/34955479>
1001. Team, C. C.-R., Food, & Drug, A. (2021). Allergic Reactions Including Anaphylaxis After Receipt of the First Dose of Pfizer-BioNTech COVID-19 Vaccine – United States, December 14-23, 2020. *MMWR Morb Mortal Wkly Rep*, 70(2), 46-51. doi:10.15585/mmwr.mm7002e1. <https://www.ncbi.nlm.nih.gov/pubmed/33444297>
1002. Thompson, M. G., Burgess, J. L., Naleway, A. L., Tyner, H., Yoon, S. K., Meece, J., . . . Gaglani, M. (2021). Prevention and Attenuation of Covid-19 with the BNT162b2 and mRNA-1273 Vaccines. *N Engl J Med*, 385(4), 320-329. doi:10.1056/NEJMoa2107058. <https://www.ncbi.nlm.nih.gov/pubmed/34192428>
1003. Tinoco, M., Leite, S., Faria, B., Cardoso, S., Von Hafe, P., Dias, G., . . . Lourenco, A. (2021). Perimyocarditis Following COVID-19 Vaccination. *Clin Med Insights Cardiol*, 15, 11795468211056634. doi:10.1177/11795468211056634. <https://www.ncbi.nlm.nih.gov/pubmed/34866957>
1004. Truong, D. T., Dionne, A., Muniz, J. C., McHugh, K. E., Portman, M. A., Lambert, L. M., . . . Newburger, J. W. (2021). Clinically Suspected Myocarditis Temporally Related to COVID-19 Vaccination in Adolescents and Young Adults. *Circulation*. doi:10.1161/CIRCULATIONAHA.121.056583. <https://www.ncbi.nlm.nih.gov/pubmed/34865500>
1005. Tutor, A., Unis, G., Ruiz, B., Bolaji, O. A., & Bob-Manuel, T. (2021). Spectrum of Suspected Cardiomyopathy Due to COVID-19: A Case Series. *Curr Probl Cardiol*, 46(10), 100926. doi:10.1016/j.cpcardiol.2021.100926. <https://www.ncbi.nlm.nih.gov/pubmed/34311983>
1006. Umei, T. C., Kishino, Y., Shiraishi, Y., Inohara, T., Yuasa, S., & Fukuda, K. (2021). Recurrence of myopericarditis following mRNA COVID-19 vaccination in a male adolescent. *CJC Open*. doi:10.1016/j.cjco.2021.12.002. <https://www.ncbi.nlm.nih.gov/pubmed/34904134>
1007. Vidula, M. K., Ambrose, M., Glassberg, H., Chokshi, N., Chen, T., Ferrari, V. A., & Han, Y. (2021). Myocarditis and Other Cardiovascular Complications of the mRNA-Based COVID-19 Vaccines. *Cureus*, 13(6), e15576. doi:10.7759/cureus.15576. <https://www.ncbi.nlm.nih.gov/pubmed/34277198>
1008. Visclosky, T., Theyyuni, N., Klekowski, N., & Bradin, S. (2021). Myocarditis Following mRNA COVID-19 Vaccine. *Pediatr Emerg Care*, 37(11), 583-584. doi:10.1097/PEC.0000000000002557. <https://www.ncbi.nlm.nih.gov/pubmed/34731877>
1009. Warren, C. M., Snow, T. T., Lee, A. S., Shah, M. M., Heider, A., Blomkalns, A., . . . Nadeau, K. C. (2021). Assessment of Allergic and Anaphylactic Reactions to mRNA COVID-19 Vaccines With Confirmatory Testing in a US Regional Health System. *JAMA Netw Open*, 4(9), e2125524. doi:10.1001/jamanetworkopen.2021.25524. <https://www.ncbi.nlm.nih.gov/pubmed/34533570>
1010. Watkins, K., Griffin, G., Septaric, K., & Simon, E. L. (2021). Myocarditis after BNT162b2 vaccination in a healthy male. *Am J Emerg Med*, 50, 815 e811-815 e812. doi:10.1016/j.ajem.2021.06.051. <https://www.ncbi.nlm.nih.gov/pubmed/34229940>
1011. Weitzman, E. R., Sherman, A. C., & Levy, O. (2021). SARS-CoV-2 mRNA Vaccine Attitudes as Expressed in U.S. FDA Public Commentary: Need for a Public-Private Partnership in a Learning Immunization System. *Front Public Health*, 9, 695807. doi:10.3389/fpubh.2021.695807. <https://www.ncbi.nlm.nih.gov/pubmed/34336774>

1012. Welsh, K. J., Baumblatt, J., Chege, W., Goud, R., & Nair, N. (2021). Thrombocytopenia including immune thrombocytopenia after receipt of mRNA COVID-19 vaccines reported to the Vaccine Adverse Event Reporting System (VAERS). *Vaccine*, 39(25), 3329-3332. doi:10.1016/j.vaccine.2021.04.054. <https://www.ncbi.nlm.nih.gov/pubmed/34006408>
1013. Witberg, G., Barda, N., Hoss, S., Richter, I., Wiessman, M., Aviv, Y., . . . Kornowski, R. (2021). Myocarditis after Covid-19 Vaccination in a Large Health Care Organization. *N Engl J Med*, 385(23), 2132-2139. doi:10.1056/NEJMoa2110737. <https://www.ncbi.nlm.nih.gov/pubmed/34614329>
1014. Zimmermann, P., & Curtis, N. (2020). Why is COVID-19 less severe in children? A review of the proposed mechanisms underlying the age-related difference in severity of SARS-CoV-2 infections. *Arch Dis Child*. doi:10.1136/archdischild-2020-320338. <https://www.ncbi.nlm.nih.gov/pubmed/33262177>

Anlage 2 Impfung im Gesundheitswesen

Quelle: <https://www.wodarg.com/>, zuletzt abgerufen am 15.1.2022 um 11.54 Uhr.

Indizien für laufende gentechnische Großversuche mit Ahnungslosen

Einige Quellen zu den von mir erwähnten Arbeiten über nicht zufällige Toxizitätsschwankungen der sogen. "Impfstoffe" von Pfizer, Moderna und Janssen finden Sie hier bei Craig Paardekooper:

<https://www.howbadismybatch.com/>

9.1.2022 (Änderungen und Ergänzungen vom 13.1.2022)

Craig Paardekooper und andere haben die US-amerikanische Datenbank VAERS, in der die Schäden in engem zeitlichen Zusammenhang mit der Verabreichung der Präparate von BioNTech/Pfizer, Moderna und Janssen dokumentiert werden, einer genauen Analyse unterzogen. Dabei hat sich herausgestellt, dass die einzelnen Chargen der sogenannten Impfungen eine extrem unterschiedliche Toxizität aufweisen. Bei einigen Chargen ist die Toxizität um bis zu 3000-fach erhöht. Die Impfentscheidung wird dabei zum russisch Roulette.

Die Abweichungen sind so extrem, dass es sich dabei nicht um zufällige oder anwendungsbedingte Toxizitätsschwankungen handeln kann. Es spricht vielmehr einiges dafür, dass derzeit im Schutze der behaupteten Notlage gentechnische Großversuche an der breiten, ahnungslosen Bevölkerung durchgeführt werden und dass dies durch die rechtlich-politische Vorarbeit und Mithilfe der Regierungen und Behörden ermöglicht, gar befördert worden ist.

Die alterproben Regeln, die sorgfältige, langjährige Studien für die Zulassung eines Medikamentes voraussetzten, wurden unter dem Pandemie-Vorwand außer Kraft gesetzt. Jetzt kann vieles ausprobiert werden und davon wird reichlich Gebrauch gemacht. Pharmafirmen nutzen derzeit diese noch nie dagewesene Chance, um unbürokratisch über 120 experimentelle Corona Impfstoffkandidaten erproben zu können. Bayer Chef Stefan Oelrich (Video nach 1:37:40 h) hat in seiner Rede beim World Health Summit 2021 in Berlin die mRNA-Vakzine als „Gentherapie bezeichnet, die 95 % der Bevölkerung noch 2 Jahren vorher abgelehnt hätten“. Auf der Angstwelle reitend probieren profitorientierte Pharmaunternehmen derzeit alles aus an Methoden und Produkten, was sich patentieren lässt und haben es über die parallel laufenden Datensammelaktionen sehr leicht, die Wirkung ihrer Experimente zu beobachten – ohne dafür haften zu müssen. Widerstand durch Ethikkommissionen ausgeschlossen.

Das Einfallstor für die experimentierfreudige Pharmaindustrie ist das sogenannte „teleskopische Zulassungsverfahren“. Wenn sonst die Entwicklung neuer Impfstoffe viele Jahre (konkret mindestens fünf Jahre, durchschnittlich acht Jahre) dauerte und nach strengen abgestuften Regeln verlief, hat die WHO mit Ausrufung des „Pandemie-Notstandes“ das „teleskopische Zulassungsverfahren“ ermöglicht.

Nach bisher geltenden Praxis klinischer Studien gab es mindestens vier Phasen, die nacheinander jeweils die geforderten Sicherheitslevel für die jeweils nächste Stufe erbringen mussten, vergleiche die Ausführungen auf der Webseite des Bundesministeriums für Bildung und Forschung:

- Phase I-Studien sind kleine Studien, in denen eine neue Behandlung erstmals am Menschen, und zwar an gesunden Freiwilligen, eingesetzt wird. In diesem Stadium werden grundlegende

Eigenschaften wie Verträglichkeit und Sicherheit eines neuen Medikaments überprüft, um zu sehen, ob es sich für einen Einsatz beim Menschen eignet.

- *Phase II-Studien sind etwas größer als Phase I-Studien. Sie haben meist 100 bis 300 Teilnehmende. In der Phase II wird ein Medikament zum ersten Mal bei Patientinnen und Patienten überprüft, die an jener Erkrankung leiden, für deren Behandlung das Medikament entwickelt wird. Dabei geht es um die optimale Dosierung. Zusätzlich werden erste Daten zur Wirksamkeit erhoben.*
- *Phase III-Studien sind große Studien. Sie geben relativ präzise Auskunft über Wirksamkeit und Verträglichkeit. In den allermeisten Fällen sind es Vergleichsstudien. Dabei werden Patientinnen und Patienten, die die zu untersuchende Behandlung erhalten, mit einer Kontrollgruppe verglichen, die eine andere Behandlung erhält.*
- *Phase IV-Studien finden statt, wenn ein Medikament bereits auf dem Markt ist. Für Phase IV-Studien gibt es unterschiedliche Gründe. So kann es sinnvoll sein, ein bereits zugelassenes Medikament bei Patientinnen und Patienten mit bestimmten Eigenschaften noch einmal gezielt zu untersuchen. In Phase IV-Studien können außerdem seltene Nebenwirkungen eines Medikaments besser beurteilt werden, weil mehr Patientinnen und Patienten behandelt werden.*

Eigentlich sollten wir uns bei den Spritzen von Moderna, BioNtech-Pfizer, Janssen oder AstraZeneka nach deren „bedingter Marktzulassung“ in einer Phase IV-Studie (Postmarketing-/Beobachtungs-Studie) befinden. Zur bedingten Zulassung erklärt die in Deutschland zuständige Arzneimitteloberbehörde, das Paul-Ehrlich-Institut (PEI) – in kursiv: Anmerkungen des Autors):

„Eine bedingte Zulassung ist eine Zulassung, die an Auflagen geknüpft ist. Sie kann im Interesse der Allgemeinheit für ein Arzneimittel erteilt werden,

- *wenn der Vorteil der sofortigen Verfügbarkeit des Arzneimittels das Risiko weniger umfangreicher Daten als normalerweise erforderlich überwiegt. (Wo ist die Nutzen-Schadens-Abwägung?)*
- *– wenn es um die Behandlung oder Vorbeugung einer lebensbedrohlichen Krankheit geht. Dazu gehören auch Arzneimittel für seltene Krankheiten, (bei COVID-19 ist es nicht zu mehr Kranken und Todesfällen gekommen als bei einer normalen Grippe)*
- *wenn der CHMP feststellt, dass alle folgenden Anforderungen erfüllt sind:*
- *Eine positive Nutzen-Risiko-Bilanz des Produkts, d.h. der Nutzen für die öffentliche Gesundheit durch die sofortige Verfügbarkeit des Arzneimittels auf dem Markt überwiegt die Risiken, die aufgrund der vorgesehenen Nachreichung weiterer Daten bestehen. (ist nicht nachweisbar und wurde nicht nachgewiesen)*
- *Der Antragsteller legt umfassende Daten zu einem späteren Zeitpunkt vor. (was? wann? siehe VERS-Daten))*
- *Ein ungedeckter medizinischer Bedarf wird erfüllt (das ist offenkundig nicht der Fall, vielmehr wurde und wird massiv fehlbehandelt und dadurch erst Schaden verursacht) Bedingte Zulassungen sind ein Jahr lang gültig und können jährlich erneuert werden. Sie können in eine Vollzulassung übergehen.*

Obwohl beim „teleskopierten“ Verfahren die Studienphasen zusammengeschoben werden, muss natürlich bei einem zur Prüfung anstehenden Kandidaten bereits feststehen, welche Bestandteile dieser enthalten soll, und alle zugelassenen Medikamente müssen einen entsprechend identischen

Inhalt aufweisen. Rückstellproben jeder Charge sollen dies ebenso dokumentieren wie regelmäßige Kontrollen durch die Arzneimittelbehörden.

Das PEI hat auf Nachfrage jedoch mitgeteilt, dass es diese Arzneimittelkontrolluntersuchungen nicht selbst durchführt, sondern sich dabei auf die vorgeschriebenen Qualitätskontrollen und Berichte verläßt, zu denen die Hersteller verpflichtet seien.

Eine Anfrage nach der Informationsfreiheitsgesetz hinsichtlich der Inhaltsüberwachung von Corona-Impfstoffchargen vom 15. Oktober 2021 hat das PEI bis zum heutigen Tage nicht beantwortet. Wie bei anderen Corona-Maßnahmen sind Evidenz und Transparenz offenbar nicht gefragt.

Inzwischen haben mehrere internationale Forscher-Teams die USA-Nebenwirkungsdatenbank VAERS systematisch untersucht und schon am 31. Oktober 2021 festgestellt, dass sämtliche ernststen Nebenwirkungen und Todesfälle, die in den USA gemeldet wurden, nur auf einen sehr kleinen Teil der Chargen (Batches or Lots) zurückzuführen sind (Hier ein Bericht von der offiziellen VAERS-Seite). Jetzt werden immer mehr solcher Ergebnisse bekannt und ergeben erschreckende Zusammenhänge.

Die VAERS-Datenbank lieferte Beweise für Impfstoffchargen mit sehr unterschiedlicher Wirkung. Sie enthält Aufzeichnungen zu den gemeldeten Nebenwirkungen im Zusammenhang mit jeder Charge. So war es eine naheliegende Aufgabe, ein Diagramm zu erstellen, das zeigt, wie die Toxizität der Chargen im gesamten Jahr 2021 zeitlich und örtlich variierte. Aus Diagrammen geht hervor, wann die toxischen Chargen eingesetzt wurden und wie toxisch sie waren. Man findet auch Hinweise darauf, dass die teilnehmenden Pharmafirmen offenbar abgestimmt gehandelt haben. (Um nicht in das vorgegebene Zeitfenster des jeweils anderen einzugreifen?) Schließlich kann man sogar den Zweck dieser Verteilungen vermuten, z. B. die Prüfung der Auswirkungen unterschiedlicher Dosierungen (Art der Schäden und Todesfälle) usw.“

Der ehemalige Forschungschef von Pfizer Mike Yeadon meint dazu:

"Was die Absicht, Schaden zu verursachen, einschließlich des Todes, betrifft, so bin ich davon überzeugt. Ich bin auch nicht allein: mehrere völlig unabhängige Analysten stimmen in diesen Punkten überein:

1. Mehrere von uns sind der Ansicht, dass die ganze Situation der "Hot Lots" auf Vorsatz hindeutet, aber die Daten müssen gut verstanden werden. Die ursprüngliche Analyse von Craig Paardekooper ist in einem wichtigen Punkt fehlerhaft. Er hat fälschlicherweise, aber verständlicherweise, die Losnummerierung mit der zeitlichen Reihenfolge gleichgesetzt. Das ist nicht korrekt. Diese Muster, die für mich wie eine Dosis-Wirkungs-Beziehung aussehen, die im Laufe der Zeit veranschaulicht wird, wobei sich die Unternehmen offenbar abstimmen, um sich gegenseitig aus dem Weg zu gehen, entstehen also als Folge dieser unbelegten Annahme.

2. Jedoch sind diese Chargennummern und die damit verbundenen Werte für schwerwiegende unerwünschte Wirkungen REAL, und sie sind in VAERS vorhanden. Pfizer kann zum Beispiel die Daten für seine Chargen abrufen und sie gegen die SAE-Raten (Raten der schweren Nebenwirkungen) auftragen, und es würden sich Diagramme ergeben, die der Paardekooper-Auswertung sehr ähnlich sind.

3. Wir sind der Meinung, dass dies vorsätzlich geschieht, weil die Muster der SAEs, die mit den Chargennummern verbunden sind, nicht zufällig sind. Die Variabilität der SAEs pro Los ist gigantisch und kann auch nicht durch harmlose Faktoren erklärt werden. Beispielsweise können Produktinstabilität und -verschlechterung diese Effekte nicht hervorrufen. Im Allgemeinen führt der Abbau zu einem Aktivitätsverlust und nicht zum Erwerb einer stärkeren Toxizität. Man könnte zwar

argumentieren, dass dies vielleicht die Ausnahme von der Regel ist. Ich zeige, dass das nicht möglich ist, denn das gleiche außergewöhnliche Muster, dass ein geringer Prozentsatz der Chargen extrem toxisch ist, wird bei drei Produkten mit zwei Technologien (mRNA und DNA) beobachtet. Nein: Das ist Absicht und muss den Unternehmen bekannt sein.

4. Die unerwünschten Ereignisse pro Charge sind um Größenordnungen größer als bei jedem vergleichbaren Produkt (Grippeimpfstoff), und die Variabilität von Charge zu Charge ist so groß, dass nicht davon ausgegangen werden kann, dass in allen Fläschchen das gleiche Produkt enthalten ist.

5. Wir haben die Chargengrößen für 33 Pfizer-Chargen geprüft, und es gibt keine oder nur eine sehr geringe Korrelation mit der Chargengröße - hier liegt eindeutig etwas anderes vor. (Hervorhebung WW)

6. Daraus folgt, dass diese Produkte als VERFÄLSCHT betrachtet werden sollten, unabhängig davon, ob dies absichtlich oder versehentlich geschieht. Pfizer kann insbesondere nicht nachweisen, dass das, was sie als ihr Produkt anpreisen, tatsächlich in den Fläschchen enthalten ist und zwischen den einzelnen Fläschchen übereinstimmt. Dies wäre bereits ein Verbrechen, auch wenn kein Vorsatz vorliegt." (persönliche Mitteilung)

Erschreckend ist, dass alle drei Unternehmen ähnliche Studien mit stark erhöhter Toxizität durchführen. Sie gehen dabei offenbar so vor, dass sie sich nicht gegenseitig in die Quere kommen und verteilen ihre toxischen Experimente anscheinend so, dass es auf den ersten Blick kaum auffällt.

Die jetzt in den USA vermuteten Dosisfindungsstudien müssten üblicherweise vor den Zulassungsstudien der Phase III längst abgeschlossen sein (s.o.). Sie sollten mit einer sehr begrenzten Zahl von gut aufgeklärten Freiwilligen als Phase II-Studien vorgenommen werden.

Daher kommt mein dringender Verdacht, dass die Falsche Pandemie genutzt wird, viel auszuprobieren was sonst viel zu riskant und nicht erlaubt worden wäre.

Die zwischengeschalteten "Kochsalzchargen" haben dabei für die Firmen fünf Effekte:

- 1. Sie verdünnen die sonst zu alarmierenden Nebenwirkungen*
- 2. sie kosten wenig und sie bringen trotzdem den vollen Preis,*
- 3. sie liefern die Kontrollgruppen, die Big Pharma sonst in Stufe 2 bzw.3 teuer bezahlen musste,*
- 4. sie werden auch noch voll aus Steuergeldern finanziert und*
- 5. die Risiken dieser „teleskopierten“ Studien werden von der öffentlichen Hand getragen.*

Wir haben aber jetzt durch VAERS deutliche Hinweise für erst nach der Zulassung umfangreich und geplant durchgeführte Studien-Strukturen in den staatlich verordneten und finanzierten Massenimpfungen mit völlig neuen Produkten von Biontech, Janssen und Moderna.

Das ist verboten und strafbar und bricht eindeutig den Nürnberger Code und alle entsprechenden Gesetze zur Durchführung von Studien beziehungsweise zur Vermarktung von Arzneimitteln. Es handelt sich offensichtlich nicht um ein Versehen oder eine Vernachlässigung von Qualität sondern um ein geplantes Vergehen. In dieser Phase institutioneller Korruption wittern viele Unternehmen riesige Chancen und kündigen ihren Investoren bereits eine Verstetigung des gesundheitlich hochriskanten mRNA-Hypes an. Das Primärinteresse einer Arzneimittelfirma ist naturgemäß der

wirtschaftliche Erfolg und nicht der gesundheitliche Nutzen. Ob bei den laufenden teleskopierten Studien auch andere Stoffe, wie Graphenoxid oder weitere Nanopartikel eine Rolle spielen, wird seit einigen Monaten von vielen diskutiert, nachdem diese in den Covid-19 Spritzen gefunden worden sind. Das Vertrauen in die Verlässlichkeit von Studienergebnissen oder selbst von im Markt befindlichen Medikamenten ist jetzt bei vielen Menschen dahin. Mir erscheint das berechtigt, denn selbst die Suche nach gefälschten oder gepanschten (counterfeit or adulterated) Medikamenten durch eine hierfür speziell eingerichtete Abteilung von Interpol wird durch die Arzneimittelindustrie mitfinanziert.

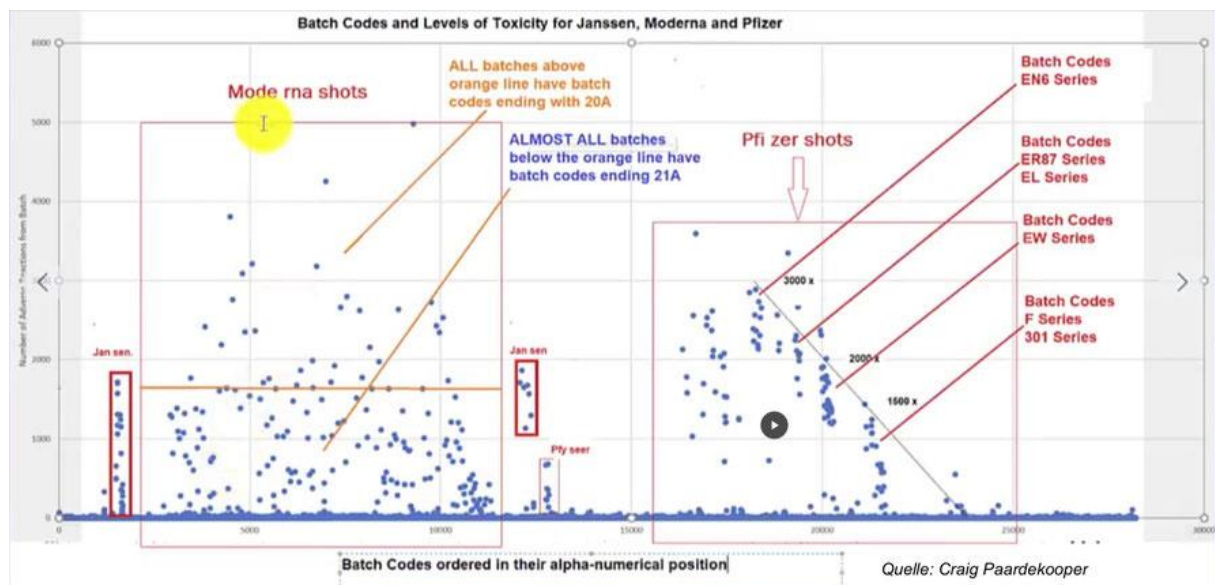
Unter dem Begriff „teleskopiertes Verfahren“ werden bei „Corona“ die Sicherheitsstufen der Studienphasen mit amtlicher Billigung ausgehebelt. Aber nicht nur das.

Auch die sonst in Phase IV (Postmarketing) übliche strenge Überwachung und transparente, planmäßig erfolgende Dokumentation der chargenbezogenen Inhaltskontrollen wird offenbar völlig den Sponsoren, sprich den Pharmafirmen überlassen. Sie dürfen ja unter dem Vorwand der mutierenden Erreger sogar neue Rezepturen (Nukleinsäuresequenzen?) anwenden. In einem intransparenten Verfahren darf offenbar alles bei allen ausprobiert werden, ohne dass jedesmal eine Ethik-Kommission oder gar die betroffenen Patienten über die Risiken bzw den Stand der Forschung und seine Risiken informiert zustimmen können/müssen. Eine entsprechende Aufklärung der Millionen Probanden findet jedenfalls nicht statt. Man nötigt diese sogar unaufgeklärt zur Teilnahme. Das alles war nie erlaubt und stellt ein Verbrechen dar, wie es z.B. Gegenstand der Nürnberger Prozesse war.

Die Erfindung des teleskopierten Verfahrens stellt sich als Trick zu Lasten der Sicherheit dar. Dieser Trick wird jedoch zum Verbrechen, wenn Millionen Ahnungslose dabei ihr Leben riskieren müssen.

Craig Paardekooper, einer der Forscher, hat eine Datenbank ins Internet gestellt, die allerdings bei Google schwer zu finden ist. Unter <https://www.howbadismybatch.com/> kann man nun selbst überprüfen, welche Chargen zu wie vielen Nebenwirkungen beziehungsweise Todesfällen geführt haben.

Zum Selbstschutz sollte jeder, der sich trotz des inzwischen bekannten großen Schädigungspotentials der sogenannten Corona-Impfung unterziehen möchte vor der genetischen Behandlung seinen Arzt oder Apotheker fragen, welche dokumentierte Wirkung die von diesem verwendeten Chargen haben. Wenn Ärzte und Apotheker an dieser Stelle nachforschen müssen, besteht die Chance, dass sie sich als möglicherweise Haftbare ihrer Verantwortung bewußt werden.



*Nachtrag: Die Bedeutung des Verfallsdatums einer Charge
(Übersetzung einer Meldung von Craig Paardekooper vom 9.1.2022)*

Wir haben also eine Liste mit den Verfallsdaten aller Impfstoffchargen. Was soll's! Nun, hier ist, warum diese Liste wichtig ist...

Die Regierung stellt den Ärzten eine Liste mit den Verfallsdaten aller Impfstoffchargen zur Verfügung. Die CDC hält diese Liste jedoch vor der breiten Öffentlichkeit geheim (warum wohl?). Eine Kontaktperson gab diese Liste an mich weiter. Mir ist aufgefallen, dass die Chargen auf der Verfallsliste ALLE diejenigen sind, die in jeder alphabetischen Gruppe die höchste Anzahl von Berichten über unerwünschte Reaktionen (UAW) aufweisen. Ich fragte mich, warum das so ist? Warum war keine der anderen Parteien auf der Verfallsliste - die mit nur einer Handvoll von Meldungen? (Ich hatte zuvor vermutet, dass es sich bei den anderen um Placebos handeln könnte.)

Dann fiel mir ein, dass Placebos nicht verfallen. Salzwasser verfällt nicht. Es hat also kein Verfallsdatum. Nur die biologisch aktiven Chargen werden auf der Verfallsliste stehen. Das ist möglicherweise der Grund, warum die CDC nicht wollte, dass die Öffentlichkeit diese Liste zu Gesicht bekommt. Sie geben sie nur an Mediziner heraus - aus "Sicherheits"-Gründen - weil sie zeigt, welche Placebos sind und welche biologisch aktiv sind.

Wenn eine Charge nicht auf der Liste steht, ist sie ein Placebo? (Fragezeichen von Wodarg)

Wir haben jetzt also eine Liste aller biologisch aktiven Chargen. Dies ist natürlich eine gute Information für Menschen, die toxische Chargen vermeiden wollen. Überprüfen Sie einfach Ihre Charge anhand der Verfallsliste. Wenn sie dort nicht aufgeführt ist, handelt es sich mit hoher Wahrscheinlichkeit um ein Placebo.

Hinweis: Bitte denken Sie daran, dass neue Chargen eingeführt werden, die möglicherweise nicht auf der bestehenden Liste stehen, und dass es selbst bei den biologisch aktiven Chargen noch erhebliche Unterschiede in der Toxizität gibt - eine schlechte Charge ist möglicherweise nicht gleich toxisch wie eine andere.

Hinweis: Diese Verfallsliste gilt möglicherweise nur für Chargen aus den USA. Sie gilt möglicherweise nicht für europäische Chargen, die oft andere Chargencodes haben.

Bemerkung Wodarg:

Und erneut die Bitte, sprechen Sie ggf. ihren Impfarzt auf diese Chargen an und bestehen Sie auf einer nebenwirkungsarmen Charge.